

CRASH DATA RESEARCH CENTER

Veridian
Engineering Division
Buffalo, New York 14225

**VERIDIAN ON-SITE AIR BAG RELATED CHILD
SERIOUS INJURY INVESTIGATION**

VERIDIAN CASE NO. CA00-056

VEHICLE - 1999 FORD CONTOUR SPORT SE

LOCATION - STATE OF GEORGIA

CRASH DATE - JULY, 2000

Contract No. DTNH22-94-D-07058

Prepared for:

U.S. Department of Transportation
National Highway Traffic Safety Administration
Washington, D.C. 20590

DISCLAIMER

This document is disseminated under the sponsorship of the Department of Transportation in the interest of information exchange. The United States Government assumes no responsibility for the contents or use thereof.

The opinions, findings, and conclusions expressed in this publication are those of the authors and not necessarily those of the National Highway Traffic Safety Administration.

The crash investigation process is an inexact science which requires that physical evidence such as skid marks, vehicular damage measurements, and occupant contact points are coupled with the investigator's expert knowledge and experience of vehicle dynamics and occupant kinematics in order to determine the pre-crash, crash, and post-crash movements of involved vehicles and occupants.

Because each crash is a unique sequence of events, generalized conclusions cannot be made concerning the crashworthiness performance of the involved vehicle(s) or their safety systems.

TECHNICAL REPORT STANDARD TITLE PAGE

1. <i>Report No.</i> CA00-056	2. <i>Government Accession No.</i>	3. <i>Recipient's Catalog No.</i>	
4. <i>Title and Subtitle</i> Veridian On-Site Air Bag Related Child Serious Injury Investigation Vehicle - 1999 Ford Contour Sport SE Location - State of Georgia		5. <i>Report Date:</i> November, 2001	
		6. <i>Performing Organization Code</i>	
7. <i>Author(s)</i> Crash Data Research Center		8. <i>Performing Organization Report No.</i>	
9. <i>Performing Organization Name and Address</i> Crash Data Research Center Veridian Engineering Division P.O. Box 400 Buffalo, New York 14225		10. <i>Work Unit No.</i> C01115.0319.(0000-0009)	
		11. <i>Contract or Grant No.</i> DTNH22-94-D-07058	
12. <i>Sponsoring Agency Name and Address</i> U.S. Department of Transportation National Highway Traffic Safety Administration Washington, D.C. 20590		13. <i>Type of Report and Period Covered</i> Technical Report Crash Date - July, 2000	
		14. <i>Sponsoring Agency Code</i>	
15. <i>Supplementary Notes</i> On-site investigation of a frontal collision (into a fixed object) that involved a 1999 Ford Contour Sport SE 4-door sedan equipped with redesigned frontal air bags for the driver and front right passenger positions.			
16. <i>Abstract</i> This on-site investigation focused on the injury mechanisms of a 12 year old female front right child passenger of a 1999 Ford Contour Sport SE 4-door sedan. The vehicle was equipped with redesigned frontal air bags for the driver and front right passenger positions which deployed as a result of a frontal collision with a tree cluster. The driver of the Ford was operating the vehicle northbound on a two lane rural roadway and negotiating a left curve when she allowed the vehicle to depart the right (east) pavement edge. The Ford continued into a wooded area where the front right area impacted a tree cluster resulting in severe damage. The unrestrained 15 year old female driver initiated a forward trajectory in response to the 12 o'clock impact force and loaded the deployed redesigned driver air bag and knee bolster. Loading of the knee bolster resulted in bilateral knee abrasions. She was transported to the emergency room of a local hospital for treatment and released. The unrestrained 12 year old female front right child passenger was out-of-position forward due to the pre-crash braking actions of the driver. At impact, she was within the path of the expanding redesigned passenger air bag which struck her face and upper torso area. She sustained a nasal fracture and a multitude of underlying brain trauma to include cerebral contusions, cerebral parenchymal/subarachnoid hemorrhages, a cerebellar petechial hemorrhage and diffuse axonal injury, and a brain stem infarction. After initial treatment at a local hospital, the child passenger was subsequently transferred to a pediatric intensive care facility and admitted for 34 days.			
17. <i>Key Words</i> Collision Deformation Classification (CDC): 12-FZEN-4 WinSMASH damage algorithm: 51.4 km/h (31.9 mph) Passenger out-of-position Brain stem infarction		18. <i>Distribution Statement</i> General Public	
19. <i>Security Classif. (of this report)</i> Unclassified	20. <i>Security Classif. (of this page)</i> Unclassified	21. <i>No. of Pages</i> 9	22. <i>Price</i>

TABLE OF CONTENTS

BACKGROUND	1
SUMMARY	
Crash Site	1
Pre-Crash	2
Crash	2
Post-Crash	3
VEHICLE DATA	3
VEHICLE DAMAGE	
Exterior	3
Interior	4
MANUAL RESTRAINT SYSTEMS	4
SUPPLEMENTAL RESTRAINT SYSTEMS	5
DRIVER DEMOGRAPHICS	6
Driver Injuries	6
Driver Kinematics	6
FRONT RIGHT PASSENGER DEMOGRAPHICS	7
Front Right Passenger Injuries	7
Front Right Passenger Kinematics	8
Medical Treatment	8
SCENE DIAGRAM	9

**VERIDIAN ON-SITE AIR BAG RELATED CHILD
SERIOUS INJURY INVESTIGATION
VERIDIAN CASE NO. CA00-056
VEHICLE - 1999 FORD CONTOUR SPORT SE
LOCATION - STATE OF GEORGIA
CRASH DATE - JULY, 2000**

BACKGROUND

This on-site investigation focused on the injury mechanisms of a 12 year old female front right child passenger of a 1999 Ford Contour Sport SE 4-door sedan. The vehicle was equipped with redesigned frontal air bags for the driver and front right passenger positions which deployed as a result of a frontal collision with a tree cluster. The driver of the Ford was operating the vehicle northbound on a two lane rural roadway and negotiating a left curve when she allowed the vehicle to depart the right (east) pavement edge. The Ford continued into a wooded area where the front right area impacted a tree cluster resulting in severe damage. The unrestrained 15 year old female driver initiated a forward trajectory in response to the 12 o'clock impact force and loaded the deployed redesigned driver air bag and knee bolster. Loading of the knee bolster resulted in bilateral knee abrasions. She was transported to the emergency room of a local hospital for treatment and released. The unrestrained 12 year old female front right child passenger was out-of-position forward due to the pre-crash braking actions of the driver. At impact, she was within the path of the expanding redesigned passenger air bag which struck her face and upper torso area. She sustained a nasal fracture and a multitude of underlying brain trauma to include cerebral contusions, cerebral parenchymal/subarachnoid hemorrhages, a cerebellar petechial hemorrhage and diffuse axonal injury, and a brain stem infarction. After initial treatment at a local hospital, the child passenger was subsequently transferred to a pediatric intensive care facility and admitted for 34 days.

The crash notification was provided to NHTSA on Wednesday, November 1, 2000 and immediately assigned to the Veridian SCI team as an on-site investigative effort. The on-site investigator departed on November 7 and completed field activities Wednesday, November 8, 2000. ***Although the police accident report listed the children's father as the driver of the vehicle (uninjured - age unknown), SCI field data collected revealed the children as the sole occupants of the vehicle.***

SUMMARY

Crash Site

This single vehicle crash occurred during the early evening hours of July, 2000. At the time of the crash, it was daylight (dusk) with no adverse conditions as the road was dry. The crash occurred off the east pavement edge of a two lane north/south rural roadway (see **Figure 14 - page 9**) which curved left for northbound traffic. A hillcrest was located approximately 130.0 meters (142.2 yards) south of the crash site with a negative grade for northbound traffic. *The asphalt roadway was re-surfaced prior to the SCI inspection.* Environmental features included a wooded area located approximately 8.0 meters (26.2 feet) off the east pavement edge with a 86.0 cm (33.9 in) high embankment surrounding the impacted trees. No curve warning signs were present at the crash site which had an (unposted) speed limit of 89 km/h (55 mph).

Pre-Crash

The 15 year old female driver of the 1999 Ford Contour was operating the vehicle northbound (**Figure 1**) when she approached the apex of the road curvature (at the hillcrest) and allowed the vehicle to depart the right (east) pavement edge. The vehicle traveled 71.0 meters (233.0 feet) alongside the apron before the vehicle re-entered the roadway in a slight counterclockwise yaw, evidenced by the police reported re-entry tire marks approximated during the SCI scene inspection. Subsequent right steering maneuvers re-directed the vehicle back towards the east pavement edge. The Ford again exited the east pavement edge (**Figure 2**) and continued 22.0 meters (72.2 feet) into a wooded area. This trajectory was evidenced by 11.9 meters (39.0 feet) of pre-impact soil furrows documented at the scene. The driver reported to police that she struck a pothole in the road which contributed to pre-crash circumstances, however, evidence suggested this was more of an issue related to excessive speed and driver inexperience.



Figure 1. Northbound approach for the 1999 Ford Contour Sport SE.



Figure 2. Northbound approach for the 1999 Ford Contour Sport SE.

Crash

As the Ford approached the wooded terrain, the frontal area was deflected slightly upward by the embankment (no impact) as the front right area impacted a tree cluster (**Figures 3 & 4**) resulting in severe damage. The WinSMASH damage and trajectory algorithm computed an impact speed of 67.8 km/h (42.1 mph) with an overall velocity change of 51.4 km/h (31.9 mph) and a matching negative longitudinal component. The speed change exceeded the threshold for deployment, therefore, the Ford's redesigned frontal air bag system deployed. At this point, the Ford rotated clockwise approximately 130 degrees and came to rest 6.5 meters (21.3 feet) from the point of impact facing southeast.



Figure 3. Struck tree cluster.



Figure 4. Close-up view of struck tree cluster.

Post-Crash

The driver exited the vehicle under her own power and summoned the child passenger's father who arrived on-scene within minutes of the crash. The child passenger was removed from the vehicle by the father through the right front window opening and transported (along with the driver) to the emergency room of a local hospital. The driver was treated and released as the child passenger was subsequently transported by air to a nearby pediatric intensive care facility and admitted for 34 days. The vehicle was towed from the scene with disabling damage.

VEHICLE DATA

The 1999 Ford Contour Sport SE was manufactured on 1/99 and identified by the vehicle identification number (VIN): 1FAFP66L1XK (production number deleted). The driver's father was reported by police as the owner of the vehicle. The vehicle was a 4-door sedan equipped with front-wheel drive and a 2.5 liter, V-6 engine. At the time of the crash, the odometer had recorded 89,512 km (55,622 miles). The seating was configured with front bucket and rear bench seats. The surrogate interview reported no previous crashes or maintenance on the Ford's frontal air bag system. A cellular phone was not present in the vehicle.

VEHICLE DAMAGE

Exterior

The 1999 Ford Contour Sport SE sustained severe frontal damage as a result of the impact with the tree cluster (**Figures 5 & 6**). The direct contact damage began 12.0 cm (4.7 in) right of the end plane centerline and extended 18.0 cm (7.1 in) outboard. The impact deformed the full frontal width resulting in a combined direct and induced damage length (Field L) of 116.0 cm (45.7 in). Six crush measurements were documented at the level of the bumper: C1= 4.5 cm (1.8 in), C2= 27.5 cm (10.8 in), C3= 47.5 cm (18.7 in), C4= 77.5 cm (30.5 in), C5= 63.5 cm (25.0 in), C6= 57.5 cm (22.6 in). The Collision Deformation Classification (CDC) for this impact to the Ford was 12-FZEN-4 with a principal direction of force of 0 degrees. The hood was deformed up and rearward from engagement against the trees. The bumper corners were pulled inward by the narrow contact damage as the end structure was displaced slightly to the right from the impact force. Tree bark was noted along the contact damage. The right fender was deformed rearward which restricted the right front wheel/tire (not



Figure 5. Front right damage to the 1999 Ford Contour Sport SE.



Figure 6. Right side view of the 1999 Ford Contour Sport SE.

deflated) and jammed the right side doors. Induced contact damage also produced extensive longitudinal shifting of the right A-pillar which buckled the roof and right front window frame (tempered glazing disintegrated). The windshield was fractured from (exterior) impact forces and the (interior) front right passenger air bag deployment. Reduction in the right wheelbase measured 32.5 cm (12.8 in) as the left wheelbase was elongated 3.5 cm (1.4 in). Pre-existing damage was noted to the left rear tail light which was fractured and repaired with reflective tape.

Interior

Interior damage to the Ford Contour was severe and attributed to component intrusions and occupant contact (**Figures 7 & 8**). The left knee bolster was deformed and scuffed. Steering wheel rim deformation measured 1.5 cm (0.6 in) along the top portion as sheer capsule movement measured 3.0 cm (1.2 in). The turn signal stalk separated from the steering column. Scuff marks, abrasions, and dark hair strands were identified on the left sunvisor. The rear view mirror was displaced to the right (not fractured). The center floor-mounted console was displaced to the right. The glove compartment door was deformed, scuffed and out-of-place. The front right seat back support was displaced rearward 25.0 cm (9.8 in) and attributed to passenger rebound. Indentations were identified on the right front door panel. Minor abrading and scuffs were also documented to the rear aspect of the front left seat back, which was attributed to cargo movement within the vehicle. *It should be noted that the right mid-instrument panel area, windshield header, and headliner were free of contact evidence.* Longitudinal intrusions into the front occupant space involved 15.0 cm (5.9 in) of right toe pan/instrument panel and 12.0 cm (4.7 in) of center instrument panel intrusion. Vertical intrusions into the front right passenger space involved 3.0 cm (1.2 in) of roof intrusion.



Figure 7. Interior view of the driver space.




Figure 8. Interior view of the front right passenger space.

MANUAL RESTRAINT SYSTEMS

The interior of the Ford Contour consisted of a five passenger seating configuration with front bucket and rear bench seats. The driver 3-point manual lap and shoulder belt system consisted of a continuous loop belt webbing with a sliding latchplate and a dual mode retractor (inertial lock/belt sensitive). The front right 3-point manual lap and shoulder belt system consisted of a continuous loop belt webbing with a sliding latchplate and a retractor equipped with an inertial and switchable lock mechanism. The rear seated positions were equipped with 3-point manual lap and shoulder belt systems which consisted of a continuous loop belt webbing with a sliding latchplate that retracted into an inertial sensitive and

switchable locking retractor. Although slight dimpling was noted to the webbing of the driver restraint, no loading evidence was identified on any of the restraint webbings or D-rings to support belt usage by any occupant.

SUPPLEMENTAL RESTRAINT SYSTEMS

The 1999 Ford Contour Sport SE was equipped with redesigned frontal air bags for the driver and front right passenger positions. The air bags deployed as a result of the crash (**Figure 9**). The driver air bag was housed in the center of the steering wheel with a horizontally oriented flap tear seam (H-configuration). No contact evidence was identified on the exterior surface of the module cover flaps. The flaps were symmetrical in shape and measured 19.0 cm (7.5 in) in width and 9.0 cm (3.5 in) in height. The diameter of the driver air bag measured 56.5 cm (22.2 in) in its deflated state (**Figure 10**). Makeup transfers were documented to the upper right quadrant of the air bag face along with fabric transfers to the upper left quadrant. The bag was tethered by two internal straps and vented by two ports located at the 11 o'clock and 1 o'clock sectors on the rear aspect of the air bag.



Figure 9. 1999 Ford Contour Sport SE deployed redesigned frontal air bags.

The front right passenger air bag deployed from the right top instrument panel area with a single cover flap design hinged at the forward aspect. The cover flap was rectangular in shape and measured 43.0 cm (16.9 in) in width along the top portion, 36.7 cm (14.4 in) in width along the lower portion, 26.0 cm (10.2 in) in height along the left edge and 22.0 cm (8.7 in) in height along the right edge. An indentation was noted along the aft edge of the flap from contact to the (fractured) right mid-windshield area. The passenger air bag measured 71.5 cm (28.1 in) in width and 69.5 cm (27.4 in) in height in its deflated state (**Figure 11**). Although heavily stained by mold from exposure to the environment post-crash, contact evidence consisted of dark fabric transfers to the lower left quadrant of the air bag face with heavy abrading surrounding the contact site. The top section of the air bag membrane was also abraded from engagement against the (fractured) right windshield. The bag was tethered by two internal straps and vented by one port located at the 10 o'clock sector on the side aspect of the bag. Rearward air bag excursion measured 53.0 cm (20.9 in) from the aft portion of the right instrument panel.



Figure 10. Contact evidence to the 1999 Ford Contour deployed redesigned driver air bag.



Figure 11. Contact evidence to the 1999 Ford Contour deployed redesigned passenger air bag.

DRIVER DEMOGRAPHICS

Age/Sex:	15 year old female
Height:	168 cm (66 in)
Weight:	66 kg (145 lb)
Seat Track Position:	Middle position [11.5 cm (4.5 in) forward of the full rearward position or 10.0 cm (3.9 in) aft of the full forward position]
Manual Restraint Use:	None
Usage Source:	Vehicle inspection
Eyewear:	None
Type of Medical Treatment:	Transported to the emergency room of a local hospital and released

Driver Injuries

<i>Injury</i>	<i>Severity (AIS 90)</i>	<i>Injury Mechanism</i>
*Bilateral knee abrasions	Minor (890202.1,3)	Left knee bolster
*Left shoulder abrasion	Minor (790202.1,2)	Driver air bag

*source - interviewee**

Driver Kinematics

The 15 year old female driver of the 1999 Ford Contour Sport SE was unrestrained (3-point manual lap and shoulder belt system available) and presumed to be seated in an upright posture with the seat track adjusted to a middle position (**Figure 12**). The lack of belt usage was determined by the trajectory of the driver in conjunction with the absence of loading evidence on the restraint webbing or D-ring.

At impact, the driver initiated a forward trajectory in response to the 12 o'clock impact force and loaded the deployed redesigned driver air bag as evidenced by the makeup transfers documented to the upper right quadrant of the air bag face. Although driver injury information was limited, she sustained an abrasion to the left shoulder which probably was a result of air bag interaction, evidenced by the location of the injury relative to the fabric transfers documented to the left upper quadrant of the air bag face. The driver's torso loaded the deployed air bag and compressed the bag against the steering assembly. This loading of the steering column resulted in 3.0 cm (1.2 in) of sheer capsule movement. She subsequently impacted the knee bolster resulting in bilateral knee abrasions, evidenced by the deformation and scuff marks identified on this component. The driver continued the kinematic response pattern as her head struck the sunvisor as evidenced by the abrading and hair strands documented to this component, however, no resulting injury was reported. Following the crash, she exited the vehicle under her own power and was transported by private vehicle to the emergency room of a local hospital for treatment and released. The redesigned driver air bag provided adequate protection against contact to the steering wheel hub/rim, thus preventing serious injury.



Figure 12. Interior view of the driver space.

FRONT RIGHT PASSENGER DEMOGRAPHICS

Age/Sex: 12 year old female
 Height: 160 cm (63 in)
 Weight: 47 kg (104 lb)
 Seat Track Position: Middle position [9.0 cm (3.5 in) forward of the full rearward position or 13.0 cm (5.1 in) aft of the full forward position]
 Manual Restraint Use: None
 Usage Source: Vehicle inspection
 Eyewear: None
 Type of Medical Treatment: Transported to a local trauma center and admitted (34 days)

Front Right Passenger Injuries

<i>Injury</i>	<i>Severity (AIS 90)</i>	<i>Injury Mechanism</i>
#Parenchymal hemorrhage and edema along medial margins both frontal lobes	Critical (140646.5,3)	Expanding front right air bag
#Petechial pontine hemorrhage	Critical (140210.5,8)	Front right seat back (indirect contact to passenger air bag)
#Diffuse axonal injury in the left cerebellar hemisphere	Critical (140406.5,6)	Non-contact injury (acceleration injury - indirect contact to passenger air bag)
#Brain stem infarction	Critical (140208.5,8)	Front right seat back (indirect contact to passenger air bag)
#Petechial hemorrhage and edema cerebellum	Severe (140426.4,6)	Expanding front right air bag
#Intraventricular hemorrhage	Severe (140678.4,9)	Expanding front right air bag
^Cerebral subarachnoid hemorrhage	Serious (140684.3,9)	Front right seat back (indirect contact to passenger air bag)
^Acute cerebral edema	Serious (140660.3,9)	Expanding front right air bag
#Cerebral contusion (multiple: one on each side - NFS) (multiple: on same side - NFS)	Serious (140620.3,3)	Expanding front right air bag
#Small hepatic (liver) contusion	Moderate (541810.2,1)	Expanding front right air bag
#Nose fracture (non-displaced)	Minor (251002.1,4)	Expanding front right air bag
*Multiple abrasions right anterior lower forearm	Minor (790202.1,1)	Expanding front right air bag
*Contusion right upper anterior forearm and right shoulder	Minor (790402.1,1)	Expanding front right air bag
*Small laceration right arm (NFS)	Minor (790602.1,1)	Right front door panel

Sources - ER record*/Radiology report#/Discharge summary~/Consultation+

Front Right Passenger Kinematics

The 12 year old female front right child passenger of the 1999 Ford Contour Sport SE was unrestrained (3-point manual lap and shoulder belt system available) and presumed to be seated in an upright posture with the seat track adjusted to a middle position. The lack of belt usage was determined by the trajectory of the child in conjunction with the absence of loading evidence on the restraint webbing or D-ring.



Figure 13. Deformation to the front right seat back support.

The child passenger was out-of-position forward due to the pre-crash braking actions of the driver. At impact, the child was forward within the path of the expanding air bag which struck her face/upper torso area and propelled her rearward into the front right seat back support. The combination of air bag expansion and rearward acceleration produced extensive injury. She sustained a nasal fracture and a multitude of underlying brain injury to the cerebral cortex and cerebellar regions. Cerebral trauma involved a parenchymal hemorrhage along with multiple contusions and acute edema. Cerebellar trauma involved a petechial hemorrhage and diffuse axonal injury in the left hemisphere. Soft tissue injury consisted of abrasions to the right anterior (lower) forearm and contusions to the right anterior (upper) forearm/shoulder. These injury mechanisms were evidenced by the occupant kinematic response pattern relative to the fabric transfers documented to the lower left quadrant of the passenger air bag face. In addition, occupant interaction with the expanding air bag re-directed the deployment path into the right mid-windshield area resulting in the noted abrasions to the top aspect of the air bag membrane. Loading of the glove compartment door was confirmed by the deformation documented to this component, however, no injury was reported as a result of this contact. At this point, the air bag membrane continued to expand against the child passenger which propelled her rearward into the front right seat back support. This trajectory was evidenced by 25.0 cm (9.8 in) of extensive loading deformation identified to the seat back (**Figure 13**). Loading of the seat back support resulted in a traumatic subarachnoid and petechial hemorrhage along with an underlying brain stem infarction (*an obstruction or interruption resulting in an inadequate flow of oxygen to the brain*).

Medical Treatment

The passenger's father arrived on-scene within minutes of the crash to find the child unconscious and slumped to the left (in the front right seat) with her head resting on her left shoulder. The child was removed by the parent through the (disintegrated) right front window opening and transported by private vehicle to the emergency room of a local hospital where she was found to be breathing spontaneously with some movement of both arms. Following four hours of initial treatment, the child passenger was stabilized and subsequently transferred by air to a nearby pediatric intensive care facility for further evaluation and treatment. She arrived on full respiratory support with a Glasgow Coma Scale (GCS) of 7 with some response to painful stimuli. It should be noted that the pediatric facility noted no signs of gross trauma (abrasions or contusions) during the 34 day admit. During her treatment, intracranial pressures continued to be a concern which frequently measured in the 20's with spikes to the 40's. Measures used to control intracranial pressure included a cooling blanket, drainage of cerebrospinal fluid, and hyperventilation. Following intensive care, the front right child passenger was

transferred to a secondary care facility for an additional six weeks. Although the child is now at home, the parent reported that she is not talking or walking, has limited use of one hand, and must be fed through a gastrointestinal tube.

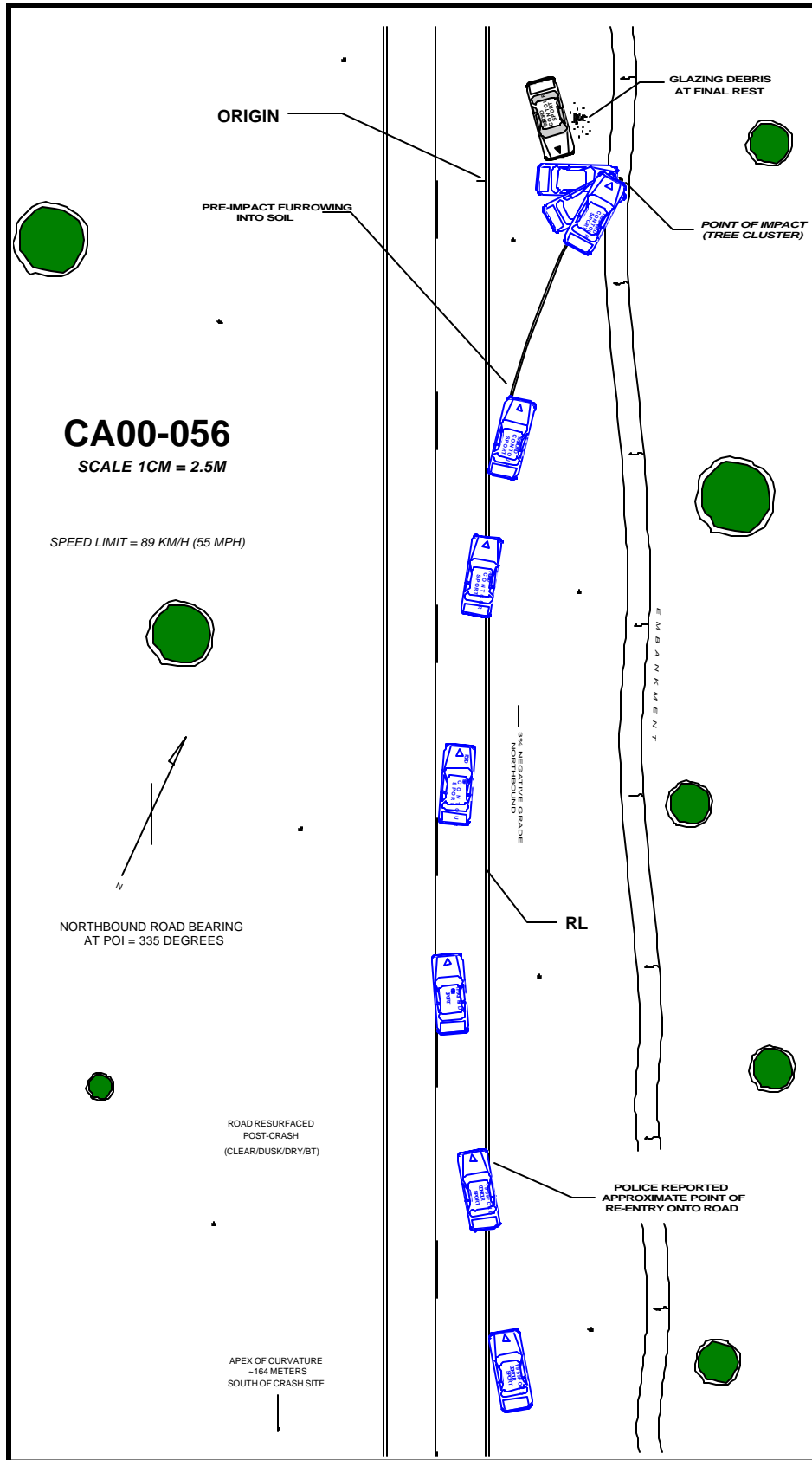


Figure 14. Scene Diagram.