

CRASH DATA RESEARCH CENTER

Calspan Corporation
Buffalo, NY 14225

**CALSPAN REMOTE SIDE IMPACT INFLATABLE OCCUPANT PROTECTION
SYSTEM CRASH INVESTIGATION**

CASE NO: 2006-02-037B

VEHICLE: 2006 PORSCHE BOXSTER

LOCATION: NEW YORK

CRASH DATE: JUNE 2006

Contract No. DTNH22-01-C-17002

Prepared for:

U.S. Department of Transportation
National Highway Traffic Safety Administration
Washington, D.C. 20590

DISCLAIMER

This document is disseminated under the sponsorship of the Department of Transportation in the interest of information exchange. The United States Government assumes no responsibility for the contents or use thereof.

The opinions, findings, and conclusions expressed in this publication are those of the authors and not necessarily those of the National Highway Traffic Safety Administration.

The crash investigation process is an inexact science which requires that physical evidence such as skid marks, vehicular damage measurements, and occupant contact points are coupled with the investigator's expert knowledge and experience of vehicle dynamics and occupant kinematics in order to determine the pre-crash, crash, and post-crash movements of involved vehicles and occupants.

Because each crash is a unique sequence of events, generalized conclusions cannot be made concerning the crashworthiness performance of the involved vehicle(s) or their safety systems.

TECHNICAL REPORT STANDARD TITLE PAGE

<p>1. Report No. 2006-02-037B</p>	<p>2. Government Accession No.</p>	<p>3. Recipient's Catalog No.</p>	
<p>4. Title and Subtitle Calspan Remote Side Impact Inflatable Occupant Protection System Crash Investigation Vehicle: 2006 Porsche Boxster Location: State of New York</p>		<p>5. Report Date: March 2007</p>	
		<p>6. Performing Organization Code</p>	
<p>7. Author(s) Crash Data Research Center</p>		<p>8. Performing Organization Report No.</p>	
<p>9. Performing Organization Name and Address Crash Data Research Center Calspan Corporation P.O. Box 400 Buffalo, New York 14225</p>		<p>10. Work Unit No. C00410.0000.0362</p>	
		<p>11. Contract or Grant No. DTNH22-01-C-17002</p>	
<p>12. Sponsoring Agency Name and Address U.S. Department of Transportation National Highway Traffic Safety Administration Washington, D.C. 20590</p>		<p>13. Type of Report and Period Covered Technical Report Crash Date: June 2006</p>	
		<p>14. Sponsoring Agency Code</p>	
<p>15. Supplementary Note This remote investigation focused on the performance of the side impact air bag system that deployed in a 2006 Porsche Boxster and the injury source of a laceration to a previously transplanted left kidney.</p>			
<p>16. Abstract This remote investigation focused on the performance of the side impact air bag system that deployed in a 2006 Porsche Boxster and the injury source of a laceration to a previously transplanted left kidney. The Porsche was equipped with a Certified Advanced 208-Complaint frontal air bag system, seat back mounted side impact air bags, and door mounted head protection air bags. The driver's frontal air bag and the left side impact air bags deployed as a result of an offset head-on crash with a 1990 Toyota Corolla, which was operated by a 21-year old male. The Toyota crossed the centerline into the Boxster's path of travel. Following the initial impact, the Boxster was redirected rearward and off the west edge of the roadway. The right rear side area of the Boxster impacted a W-beam guardrail. A 1999 Ford Explorer that was traveling behind the Boxster was impacted head-on by the Toyota following the first two events. The 49-year old male driver of the Porsche was a recent left kidney transplant patient. The kidney was repositioned to the lower left anterior aspect of the abdomen, a common practice for this procedure. The driver of the Boxster was restrained by the manual 3-point lap and shoulder belt system. He sustained safety belt contusions of the left chest, neck, and shoulder with contusions and abrasions of the anterior abdomen. Additionally, the driver sustained a contusion and laceration to the transplanted kidney, a right heel fracture, a left ankle fracture, and fractures of L1 and L2. He was transported to a local hospital where he was stabilized and then transferred by helicopter to a regional trauma center where he was admitted for 14 days. The driver of the Toyota succumbed to his injuries.</p>			
<p>17. Key Words Certified Advanced 208-Compliant occupant protection Driver and side air bag deployment Incapacitating injuries to driver</p>		<p>18. Distribution Statement General Public</p>	
<p>19. Security Classif. (of this report) Unclassified</p>	<p>20. Security Classif. (of this page) Unclassified</p>	<p>21. No. of Pages 10</p>	<p>22. Price</p>

TABLE OF CONTENTS

BACKGROUND.....	1
SUMMARY.....	2
CRASH SITE.....	2
VEHICLE DATA	2
2006 PORSCHE BOXSTER.....	2
1990 TOYOTA COROLLA	2
1999 FORD EXPLORER.....	3
CRASH SEQUENCE.....	3
PRE-CRASH	3
CRASH.....	3
POST-CRASH	4
VEHICLE DAMAGE	4
EXTERIOR DAMAGE – 2006 PORSCHE BOXSTER.....	4
INTERIOR DAMAGE – 2006 PORSCHE BOXSTER.....	5
MANUAL RESTRAINTS – 2006 PORSCHE BOXSTER.....	6
CERTIFIED ADVANCED 208-COMPLIANT FRONTAL AIR BAG SYSTEM	6
2006 PORSCHE BOXSTER.....	6
SIDE AIR BAG SYSTEM – 2006 PORSCHE BOXSTER.....	7
OCCUPANT DEMOGRAPHICS – 2006 PORSCHE BOXSTER	7
DRIVER	7
DRIVER INJURIES.....	8
SUPPLEMENTAL NOTE.....	8
DRIVER KINEMATICS	9
FIGURE 14 – NASS SCENE SCHEMATIC.....	10

**CALSPAN REMOTE SIDE IMPACT INFLATABLE OCCUPANT PROTECTION
SYSTEM CRASH INVESTIGATION
NASS/SCI COMBO CASE NO.: 2006-02-037B
VEHICLE: 2006 PORSCHE BOXSTER
LOCATION: NEW YORK
CRASH DATE: JUNE 2006**

BACKGROUND

This remote investigation focused on the performance of the side impact air bag system that deployed in a 2006 Porsche Boxster (**Figure 1**) and the injury source of a laceration to a previously transplanted left kidney. The Porsche was equipped with a Certified Advanced 208-Complaint frontal air bag system, seat back mounted side impact air bags, and door mounted head protection air bags. The driver's frontal air bag and the left side impact air bags deployed as a result of an offset head-on crash with a 1990 Toyota Corolla, which was operated by a 21-year old male. The Toyota crossed the centerline into the Boxster's path of travel. Following the



Figure 1. Front left damage to the Porsche Boxster.

initial impact, the Boxster was redirected rearward and off the west edge of the roadway. The right rear side area of the Boxster impacted a W-beam guardrail. A 1999 Ford Explorer that was traveling behind the Boxster was impacted head-on by the Toyota following the first two events. The 49-year old male driver of the Porsche was a recent left kidney transplant patient. The kidney was repositioned to the lower left anterior aspect of the abdomen, a common practice for this procedure. The driver of the Boxster was restrained by the manual 3-point lap and shoulder belt system. He sustained safety belt contusions of the left chest, neck, and shoulder with contusions and abrasions of the anterior abdomen. Additionally, the driver sustained a contusion and laceration to the transplanted kidney, a right heel fracture, a left ankle fracture, and fractures of L1 and L2. He was transported to a local hospital where he was stabilized and then transferred by helicopter to a regional trauma center where he was admitted for 14 days. The driver of the Toyota succumbed to his injuries.

The crash was identified by the Calspan NASS Zone Center during the case review and injury coding process. The injury sources were discussed with the Calspan SCI team and the case was presented to NHTSA staff members during a visit to the Zone Center. Details of the crash were forwarded to NHTSA's SCI staff on August 21 and the case was assigned to the Calspan SCI team on September 8 as a remote level investigation. This effort involved a review of the NASS CDS electronic file and the updated medical records.

SUMMARY

Crash Site

The crash occurred during daylight hours on a two-lane north/south roadway. The asphalt roadway was configured with one lane in each direction, both of which were 4 m (13') in width. Double-yellow painted centerlines delineated the travel lanes and the paved shoulders were delineated with white fog lines. A W-beam guardrail was positioned 1.5 m (4') outboard of the southbound shoulder. The roadside environment consisted of natural growth. The roadway had a slight positive grade for southbound traffic. At the time of the crash, there were no adverse weather conditions and the roadway was dry. The posted speed limit for this roadway was 89 km/h (55 mph). The NASS Crash Schematic is included as **Figure 14** at the end of this narrative report.

Vehicle Data

2006 Porsche Boxster

The subject vehicle of this three-vehicle crash was a 2006 Porsche Boxster S two-door convertible. The Boxster was manufactured in January 2006 and was identified by the Vehicle Identification Number (VIN): WPOCB29806U (production number omitted). The vehicle's mileage at the time of the NASS inspection was 620 km (385 miles). The Boxster was equipped with 3.2-liter, 6-cylinder engine linked to an automatic transmission. The rear-wheel drive vehicle had a total GVWR of 1,670 kg (3,682 lb) which distributed 775 kg (1,731 lb) to the front and 940 kg (2,072 lb) to the rear. The service brakes consisted of four-wheel disc brakes with electronic stability control (ESC), and four-wheel anti-lock (ABS). The vehicle was equipped with 46 cm (18") alloy wheels and Michelin Pilot Sport P235/40R18 tires. The vehicle was also equipped with a direct Tire Pressure Monitoring System (TPMS) that alerted the operator of an occurrence of over or under inflation on one or more tires. The vehicle manufacturer's recommended tire pressure was 207 kPa (30 PSI) for the front wheels and 255 kPa (33 PSI) for the rear wheels. The specific tire information at the time of the NASS vehicle inspection was as follows:

Position	Tire Pressure	Tread Depth	Damage
LF	0 kPa	8 mm (10/32")	Puncture in sidewall and fractured alloy wheel
RF	276 kPa (40 PSI)	7 mm (9/32")	None
LR	276 kPa (40 PSI)	7 mm (9/32")	None
RR	276 kPa (40 PSI)	7 mm (9/32")	None

The Porsche accommodated only two passengers and was configured with front bucket seats with integral head restraints. According to the NASS inspection, the left front seat back was slightly reclined and the seat was adjusted to the mid-track position. The front right seat was unoccupied and adjusted to the full rear position.

1990 Toyota Corolla

The 1990 Toyota Corolla was a four-door sedan and was identified by the VIN: JT2AE96J9L3 (production number omitted). The front-wheel drive vehicle was

equipped with a 1.6-liter, 4-cylinder Inline transverse mounted engine. The NASS team was unable to locate and inspect this vehicle; therefore no further information is available.

1999 Ford Explorer

The 1999 Ford Explorer was a four-door sport utility vehicle and was identified by the VIN: 1FMZU34E7XZ (production number omitted). The 4-wheel drive vehicle was equipped with a 4.0-liter, 6-cylinder engine. The service brakes consisted of 4 wheel disc brakes with antilock (ABS). The NASS team was unable to locate and inspect this vehicle; therefore no further information is available.

Crash Sequence

Pre-Crash

The 49-year old male driver of the Boxster was traveling in a southerly direction (**Figure 2**) at a driver estimated speed of 69 km/h (43 mph). The 21-year old male driver of the Toyota was traveling in a northerly direction on the same roadway (**Figure 3**). A 49-year old female was operating the Ford Explorer and was traveling behind the Boxster in the southbound lane. The driver of the Boxster observed the northbound Toyota cross the centerline and encroach into his travel lane. He took evasive action by steering to the right and applying the brakes in an attempt to avoid the crash. Roadway gouging at the point of impact was present near the southbound fog line.



Figure 2 - Southbound approach of the Porsche Boxster.



Figure 3 - Northbound approach of the Toyota.

Crash

The front left area of the Toyota impacted the front left area of the Porsche resulting in an off-set head-on crash. The damage extended down the left side of the Porsche engaging the left front wheel and causing structural damage to the front left fender, sill, and door. The driver's frontal air bag deployed from the impact with the Toyota and the vehicle's left side air bags, mounted in the driver's seat back and in the door panel, deployed due to induced damage to the sill. The sill housed the side air bag sensor, which was mounted slightly forward of the B-pillar.

The NASS team ran a Missing Vehicle algorithm of the WinSMASH program computed a total delta-V of 19 km/h (11.8 mph) for the Boxster and 25 km/h (15.5 mph) for the

Toyota. The specific longitudinal and lateral velocity changes were -19 km/h (-11.8) and 3 km/h (1.9) for the Boxster and -25 km/h (-15.5 mph) and 0 km/h for the Toyota. These results do not capture the severity of the crash and should not be considered representative of the crash.

The Porsche was redirected rearward and struck a W-beam guardrail with the right rear side area of the vehicle as it came to rest. The Toyota continued forward and impacted the front of the Explorer, which had steered slightly left to avoid the redirected Boxster.

Post-Crash

Rescue personnel forced open the left door of the Boxster. The 49-year old male sustained multiple incapacitating injuries and was removed from the vehicle by rescue personnel. He was transported by ground ambulance to a local hospital where he was stabilized and then transferred by helicopter to a regional trauma center. He was admitted for 14 days and then released. The driver of the Toyota was removed from the vehicle and transported by helicopter to a regional trauma center where he expired two days following the crash. The occupants of the Explorer were not injured. The Boxster and Corolla were towed from the crash scene due to damage. The Explorer was driven from the scene.

Vehicle Damage

Exterior Damage – 2006 Porsche Boxster

The 2006 Porsche Boxster sustained severe frontal and left side damage as a result of the impact with the Toyota Corolla (**Figures 4 and 5**). The field investigation followed NASS exterior documentation protocols with regard to measuring crush along the frontal plane, specifically the bumper beam. However, the severity of the damage is not reflected using this technique as the innermost crush was located outboard of the left frame rail and extended to the left front wheel. The left front wheel was fractured and the wheelbase was compressed 9 cm (3.5”). The left fender was deformed and induced damage was present down the entire left side. The induced damage buckled the driver’s door, which was later mechanically opened by rescue crews, and the sill. The actual crush exceeded the prescribed extent of 2 per NASS protocol and appeared to have extended into zone 4.

Using the established protocols, the NASS inspection revealed that the direct contact



Figure 4 – Front left view of Porsche Boxster.



Figure 5 – Left side view of Porsche Boxster.

damage began 76 cm (30") inboard of the right front bumper corner and extended 67 cm (26.4") to the front left corner. The SCI revised combined direct and induced damage encompassed the entire front end and measured 143 cm (56.3") in width. The maximum crush was located at the left front bumper corner and measured 36 cm (14.2") in depth. The crush profile consisted of six equidistant crush measurements taken along the vehicle's bumper and was as follows: C1 = 36 cm (14.2"), C2 = 17 cm (6.7"), C3 = 7 cm (2.8"), C4 = 3 cm (1.2"), C5 = 1 cm (0.4") and C6 = 0 cm. Please note that C6 was revised by the SCI team based on the images provided by the NASS investigation. The Collision Deformation Classification (CDC) for the impact with the Toyota was 12-FYEW-2.

A minor secondary impact to the Boxster resulted from the impact to the guardrail. This damage was located at the back right corner of the vehicle (**Figures 6 and 7**). The Principal Direction of Force (PDOF) for this impact was 100 degrees. The damage consisted primarily of surface scratching of the composite plastic rear bumper cover with associative component deformation. A crush profile was not recorded by the NASS team; however, the width of direct contact damage was estimated to be approximately 35 cm (14"). The CDC for the secondary impact was 03-RBLE-3.



Figure 6 - Right rear corner damage to the Porsche Boxster.



Figure 7 - Close-up of damage on right rear corner.

Interior Damage – 2006 Porsche Boxster

The 2006 Porsche Boxster sustained moderate damage as a result of passenger compartment intrusion and occupant contact. The front left door was jammed shut and its glazing shattered as a result of the impact with the Toyota. The left kick panel below the A-pillar was intruded laterally 16 cm (6.3") and the attached fuse box door separated from the panel. The accelerator and brake pedals appear to have also been loaded by the driver's lower extremities during the impact sequence (**Figure 8**). Visible white marking were present on the upper aspect of the accelerator pedal inconsistent with the wear patterns typical for low mileage vehicles. Further, the brake pedal appeared to be



Figure 8 - Pedals and floor panel of Porsche Boxster.

slightly deformed to the right which likely occurred as a result of pre-crash braking maneuvers and loading at impact. The left floor panel was slightly buckled and the driver's seatback was minimally deformed. The following table outlines the SCI revised passenger compartment intrusion by their respective magnitude:

Position	Intruded Component	Magnitude	Direction
Front left	Left kick panel	16 cm	Lateral
Front left	Floor pan	7 cm	Vertical
Front center	Console	2 cm	Vertical

Manual Restraints – 2006 Porsche Boxster

The 2006 Porsche Boxster was configured with manual 3-point lap and shoulder restraints for both frontal seating positions. The driver's safety belt was configured with a sliding latch plate and an Emergency Locking Retractor (ELR). The driver's safety belt sustained visible stretching due to occupant loading (**Figure 9**). The safety belt's retractor pretensioner fired as a result of the impact and the post-crash webbing was spooled out in a worn position. No discernable transfer evidence was identified during the NASS inspection and a review of the images yielded nothing further. The front right restraint was configured with a sliding latch plate and a switchable retractor that was in the ELR mode. This position was not occupied; therefore the retractor pretensioner did not fire.




Figure 9 - Post-crash manual lap and shoulder restraint.

**Certified Advanced 208-Compliant Frontal Air Bag System
2006 Porsche Boxster**

The 2006 Porsche Boxster was equipped with a Certified Advanced 208-Compliant (CAC) frontal air bag system that included dual stage air bags for the driver and front right passenger. The driver's air bag (**Figure 10**) deployed from the steering wheel hub through trapezoidal cover flaps. The deployed air bag membrane exhibited a grayish transfer on the upper left quadrant approximately 10 cm (4") above and 15 cm (6") to the left of the air bag's center point. The air bag was vented by two ports located at the 10 and 2 o'clock positions on the back aspect of the bag.



Figure 10 - Driver's air bag.

The CAC safety system was also configured with a weight sensor in the front right seat cushion. The system was designed to detect occupant presence and automatically suppress the front right air bag if it detected a weight consistent with a child safety seat, a

small child sitting in the seat, or if it determined that the front seat was not occupied. Since the front right seat was not occupied, the CAC system suppressed the air bag. Both front seating positions were also equipped with seat track sensors, which adjusted the air bag deployment level if the seat was in the forward track position.

Side Air Bag System – 2006 Porsche Boxster

The 2006 Porsche Boxster was equipped with seat back mounted side impact air bags and door mounted head protection air bags. The seat back mounted torso air bag deployed from a single vertical cover flap on the outboard aspect of the driver’s seat back (**Figure 11**). The circular air bag was 40 x 40 cm (16 x 16”). Vinyl striations were present on the air bag’s membrane on its upper left quadrant inboard side due to contact with the tear flap during the deployment phase.

The head protection air bag deployed from the top aspect of the door panel between the door’s interior trim and the base of window (**Figure 12**). The air bag was 50 cm vertically and 35 cm horizontally and trapezoidal in form. The NASS investigation yielded no discernable evidence from the head protection air bag.



Figure 11 - Seat back mounted air bag.



Figure 12 - Door mounted head protection air bag.

Occupant Demographics – 2006 Porsche Boxster

Driver

Age/Sex:	49-year old/Male
Height:	163 cm (64”)
Weight:	73 kg (160 lbs)
Seat Track Position:	Mid-track
Manual Restraint Use:	Manual 3-point lap and shoulder restraint
Usage Source:	Vehicle inspection / injury pattern
Eyewear:	Prescription sunglasses
Type of Medical Treatment:	Transported by ambulance to local hospital, then transferred by helicopter to a regional trauma center and admitted for 14 days.

Driver Injuries

Injury	Injury Severity(AIS 90/Update 98)	Injury Source
*Kidney laceration [5 cm (2") area along posterior aspect of upper left kidney with 14 x 5 cm (5.5 x 2") wide hematoma surrounding anterior aspect of kidney]	Moderate (541620.2,2)	Lap belt webbing
*Lumbar spine fractures to the transverse process of L1 and L2	Moderate (650620.2,8) (650620.2,8)	Non-contact impact forces
*Tibia fracture to left posterior malleolus and left medial malleolus	Moderate (853416,2.2) (853412,2.2)	Toe pan
*Fracture of right calcaneus	Moderate (851400.2,1)	Brake pedal / toe pan
+8 cm (3") wide contusion across chest from below left shoulder to above right hip	Minor (490402.1,0)	Shoulder belt webbing
+Left shoulder contusion	Minor (790402.1,2)	Shoulder belt webbing
+Right hip contusion	Minor (890402.1,1)	Shoulder belt webbing
*Abdomen abrasion and contusion	Minor (590202.1,2) (590402.1,0)	Lap belt webbing
*Neck abrasion	Minor (390202.1,2)	Shoulder belt webbing
*Laceration to right forehead	Minor (290600.1,7)	Flying glass
*~Laceration to left wrist	Minor (790600.1,2)	Instrument panel left (possible)
*Abrasion to left forearm	Minor (790202.1,2)	Expanding air bag

Source: *Medical Records

+Interview

~ Denotes SCI revised from NASS case

Supplemental Note

The 49-year old male driver of the Porsche was a recent left kidney transplant recipient. It should be noted that the kidney was repositioned to the lower left anterior aspect of the abdomen, a common practice for the transplant procedure. The transplanted kidney is placed in the lower abdomen of the recipient rather than its natural position in the back because it is easier to surgically attach it to the bladder from this location (Figure 13). In most cases, the native kidneys are left in

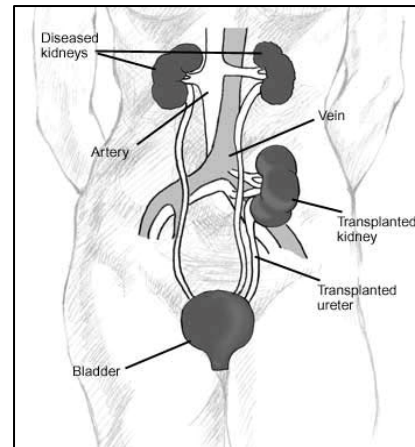


Figure 13 - Diagram of kidney transplant procedure.

place; however, it is not known whether this occupant retained his native kidneys.

Driver Kinematics

The 49-year old male driver was seated mid-track and in an upright posture and was restrained by the 3-point lap and shoulder restraint. Prior to the crash, the driver anticipated the impact and initiated evasive actions by steering to the right and braking. It is probable that the driver applied the brakes with his right foot, thereby placing the same on the brake pedal at impact.

At impact, the retractor pretensioner fired and the driver's air bag deployed. The left side air bags deployed due to the distribution of the crash forces into the left side structure of the vehicle. The driver initiated a forward trajectory in response to the 12 o'clock direction of force. He loaded the manual restraint and expanding driver air bag. The driver sustained an abrasion on his left forearm from the expanding air bag. The driver's range of motion was restricted by the combination of the deploying safety systems and the mid track position of the seat. The driver's restricted status during his forward trajectory resulted in a probable rotational flexion of the deep lower back musculature (quadratus lumbordum) and subsequent transverse process fractures of L1 and L2. As the driver rode down the impact against the taut lap and shoulder belt webbing, he also sustained a left kidney laceration and soft tissue injuries to his chest, abdomen, left shoulder, right hip, and the left aspect of his neck. Due to the location of the transplanted kidney and the associative abdominal injuries, the lap belt was the probable source of the injury. The lap and shoulder restraint was stretched, indicative of significant occupant loading. Simultaneous to loading the restraints, the driver's lower extremities were compressed against the toe pan and brake pedal resulting in a fracture to the right calcaneus, and dual fractures to the left tibia in the areas of the posterior malleolus and medial malleolus. The floor pan intruded 7 cm (3") vertically and the brake pedal was deformed slightly to the right.

After the initial impact, the Boxster was redirected rearward and to the right where it impacted the guardrail with its right rear corner and came to final rest. The severity of this secondary impact was minimal and did not result in any injuries.

The driver was removed from the vehicle by emergency personnel due to his injuries. Rescue crews mechanically opened the jammed left front door and transported the driver to a local hospital by ambulance. After he was stabilized, it was decided that he required a greater level of treatment and he was subsequently transferred by helicopter to a regional trauma center where he was admitted for 14 days.

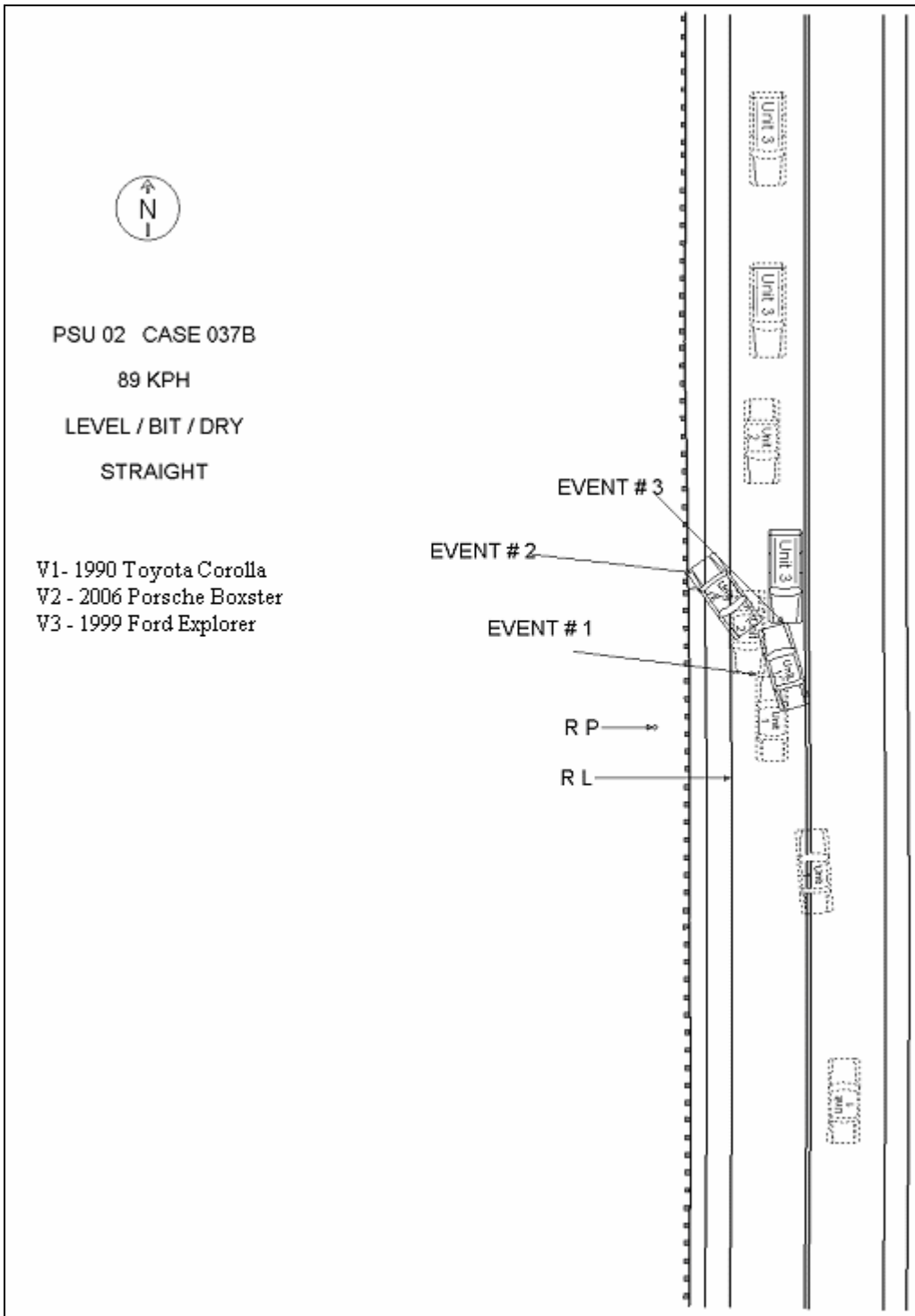


Figure 14 – NASS Scene Schematic