

**TRANSPORTATION SCIENCES
Crash Research Section**

Veridian Engineering
Buffalo, New York

**VERIDIAN REMOTE FRONT RIGHT AIR BAG DEPLOYMENT/INFANT
INVESTIGATION
VERIDIAN CASE NO. CA97-048
SUBJECT VEHICLE - 1994 TOYOTA CAMRY
LOCATION - STATE OF FLORIDA
CRASH DATE - SEPTEMBER, 1997**

Contract No.
DTNH22-94-D-07058

Prepared For:

U.S. Department of Transportation
National Highway Traffic Safety Administration
Washington, D.C. 20590

DISCLAIMER

This document is disseminated under the sponsorship of the Department of Transportation in the interest of information exchange. The United States Government assumes no responsibility for the contents or use thereof.

The opinions, findings, and conclusions expressed in this publication are those of the authors and not necessarily those of the National Highway Traffic Safety Administration.

The crash investigation process is an inexact science which requires that physical evidence such as skid marks, vehicular damage measurements, and occupant contact points are coupled with the investigator's expert knowledge and experience of vehicle dynamics and occupant kinematics in order to determine the pre-crash, crash, and post-crash movements of involved vehicles and occupants.

Because each crash is a unique sequence of events, generalized conclusions cannot be made concerning the crashworthiness performance of the involved vehicle(s) or their safety systems.

TECHNICAL REPORT STANDARD TITLE PAGE

1. <i>Report No.</i> CA97-048	2. <i>Government Accession No.</i>	3. <i>Recipient's Catalog No.</i>	
4. <i>Title and Subtitle</i> Veridian Remote Front Right Air Bag Deployment/Infant Investigation Vehicle: 1994 Toyota Camry Location: State of Florida		5. <i>Report Date:</i> March, 1998	
		6. <i>Performing Organization Code</i>	
7. <i>Author(s)</i> Crash Research Section		8. <i>Performing Organization Report No.</i>	
9. <i>Performing Organization Name and Address</i> Transportation Sciences Crash Research Section Veridian Engineering P.O. Box 400 Buffalo, New York 14225		10. <i>Work Unit No.</i> 1115 (8160-8169)	
		11. <i>Contract or Grant No.</i> DTNH22-94-D-07058	
12. <i>Sponsoring Agency Name and Address</i> U.S. Department of Transportation National Highway Traffic Safety Administration Washington, D.C. 20590		13. <i>Type of Report and Period Covered</i> Technical Report Crash Date: September, 1997	
		14. <i>Sponsoring Agency Code</i>	
15. <i>Supplementary Notes</i> A remote investigation of a two vehicle, front-to-rear type crash which involved the frontal plane of a 1994 Toyota Camry and the back plane of a 1991 Toyota Celica which resulted in the deployment of the Camry's front left and front right air bags. A three month old male was lying in a rear facing infant seat positioned in the front right seat of the Camry and sustained bilateral subdural hemorrhage (AIS-5) as a result of air bag deployment.			
16. <i>Abstract</i> This remote investigation focused on the deployment of the front left and front right air bag system of a 1994 Toyota Camry, 4-door sedan, and the subsequent critical injury of a three month old male lying in a rear facing infant seat (Century SmartFIT) which was positioned in the front right seat. The Camry impacted its front right bumper with the back left bumper of a 1991 Toyota Celica GT, 3-door liftback, in a front-to-rear type impact configuration which resulted in minor damage to both vehicles. Estimated total delta V for the Camry was 11-16 km/h (7-10 mph) and 16-19 km/h (10-12 mph) for the Celica. The impact initiated the deployment of the front left and front right air bag system of the Camry. The three month old child passenger was restrained by the infant seat's 3-point integral harness and the infant seat was secured by the available 3-point manual restraint to the front right seat. The highest AIS injuries sustained by the male infant passenger included bilateral subdural hemorrhage (AIS-5), hemorrhagic cortical contusions (AIS-3), and subarachnoid hemorrhage (AIS-3). These injuries resulted from air bag expansion against the shell of the infant seat. He was transported via private vehicle to a local hospital from the scene of the crash where he was evaluated and subsequently transferred to a trauma center. He was treated for sustained injuries at the trauma center and hospitalized for eleven days of observation. The male infant passenger has since recovered from the injuries sustained in the crash and has not experienced developmental difficulties. The vehicle was also occupied by a restrained 31 year old female driver who sustained an anterior right forearm abrasion (AIS-1) and a left shoulder sprain (AIS-1) as a result of the crash.			
17. <i>Key Words</i> 1994 Toyota Camry, Driver and passenger air bag deployment, Front left and front right air bags, Critical injury, Rear facing infant seat		18. <i>Distribution Statement</i> General Public	
19. <i>Security Classif. (of this report)</i> Unclassified	20. <i>Security Classif. (of this page)</i> Unclassified	21. <i>No. of Pages</i> 8	22. <i>Price</i>

TABLE OF CONTENTS

Background	1
Summary	2
Crash Events	3
Vehicle Damage	3
Infant Seat	4
Aftermarket Equipment	5
Restraint of the Male Infant Passenger	6
Automatic Restraint System	6
Driver Injuries	7
Driver Kinematics	7
Infant Injuries	7
Infant Kinematics	8
Medical Treatment	8

**VERIDIAN REMOTE FRONT RIGHT AIR BAG DEPLOYMENT/INFANT INJURY
INVESTIGATION
CALSPAN CASE NO. CA97-048
LOCATION: STATE OF FLORIDA
CRASH DATE: SEPTEMBER, 1997**

Background

This remote investigation focused on the deployment of the front left and front right air bag system of a 1994 Toyota Camry, 4-door sedan, and the subsequent critical injury of a three month old male lying in a rear facing infant seat (Century SmartFIT) which was positioned in the front right seat of the vehicle. The Camry impacted its front right bumper with the back left bumper of a 1991 Toyota Celica GT, 3-door liftback, in a front-to-rear type impact configuration which resulted in minor damage to both vehicles. The impact initiated the deployment of the front left and front right air bag system of the Camry. The three month old child passenger was restrained by the infant seat's 3-point integral harness and the infant seat was secured by the available 3-point manual restraint to the front right seat. The highest AIS injuries sustained by the male infant passenger included bilateral subdural hemorrhage (AIS-5), hemorrhagic cortical contusions (AIS-3), and subarachnoid hemorrhage (AIS-3). These injuries resulted from air bag expansion against the shell of the infant seat. He was transported via private vehicle to a local hospital from the scene of the crash where he was evaluated and subsequently transferred to a trauma center. He was treated for sustained injuries at the trauma center and hospitalized for eleven days of observation. The male infant passenger has since recovered from the injuries sustained in the crash and has not experienced developmental difficulties. The vehicle was also occupied by a restrained 31 year old female driver who sustained an anterior right forearm abrasion (AIS-1) and a left shoulder sprain (AIS-1) as a result of the crash.



Figure 1. Frontal view of the Toyota Camry.



Figure 2. Right lateral view of the Camry's passenger compartment and post-crash positioned infant seat.

NHTSA received notification of this September, 1997 crash via personnel at the Florida trauma study hospital on November 26, 1997 and subsequently forwarded to Calspan's Special Crash Investigation

team. The involved Toyota Camry was repaired prior to notification, and a remote investigation was therefore initiated on November 26, 1997.

Summary

This crash occurred during the daylight hours in the southbound lanes of a divided state route with a posted speed limit of 72 km/h (45 mph). There were four lanes of northbound travel, one of which was designated as a left turn lane for a private driveway that created a T-type junction. Three southbound travel lanes were divided from the northbound lanes by a grass median and were bordered by a bicycle lane and a sidewalk adjacent to the outboard travel lane. The private driveway intersected the southbound lanes of the north/southbound roadway. Traffic exiting the driveway was controlled by a stop sign. There were no traffic controls for north/southbound travel. The asphalt road surface was dry and atmospheric conditions were clear at the time of the crash.



Figure 3. Pre-impact approach of the Camry.

The 1994 Toyota Camry, 4-door sedan, was identified by vehicle identification number (V.I.N.) 4TISK12E7RU (production number omitted) and had 69,785 kilometers (43,347 miles) on the odometer at the time it was repaired by a body shop. The Camry was equipped with a Supplemental Restraint System (SRS) that consisted of a front left and front right air bag system which initiated its deployment sequence as a result of the crash. Three-point manual lap and shoulder belts were available for the front outboard seated positions. Leather seats and a 4-speed automatic transmission were also available. The Camry was not equipped with an anti-lock braking system (ABS).




Figure 4. Driver side passenger compartment of the Toyota Celica with highlighted comfort sleeve.

The 1991 Toyota Celica GT, 3 door liftback, was identified by V.I.N. JT2ST87N3M0 (production number omitted) and was equipped with a SRS that consisted of a front left air bag. Three-point manual lap and shoulder belts were available for the front outboard seated

positions. The front left belt's torso webbing was equipped with an adjustable aftermarket comfort sleeve (Figure 4). The Celica was not equipped with ABS.

Crash Events

The Celica was traveling eastbound on the private driveway approaching the junction of the north/southbound roadway. The Camry was traveling southbound in the outboard lane of traffic at a police estimated speed of 89 km/h (55 mph). The driver of the Celica initiated a right turn onto the southbound roadway prior to the Camry's encroachment into the intersection. The driver of the Camry reportedly noticed the Celica when it emerged from the eastbound private driveway, however, avoidance actions to the impending crash were not evidenced until 20.7 meters (68 feet) south of the intersection. The police accident report identified pre-impact skid marks that measured 21.3 meters (70 feet) and evidenced that the driver of the Camry applied the vehicle's brakes in an attempt to avoid an impact with the Celica. The front left, front right, and left rear wheels locked on the dry asphalt surface. The front right bumper of the Camry impacted with the back left bumper of the Celica in a 12 o'clock/6 o'clock impact configuration and resulted in minor damage to both vehicles. The estimated 11-16 km/h (7-10 mph) delta V sustained by the Camry was sufficient to deploy the front left and front right air bags. Estimated delta V for the back plane impact to the Celica was 16-19 km/h (10-12 mph). Delta V's for both vehicles were estimated from police and insurance photographs. Post-impact, the front tires of the Camry remained locked and an additional 17.7 meters (58.0 feet) of post-impact skidding was police reported. Yawing evidence from the left rear and right rear tires present at the crash scene indicated that the Camry rotated approximately 20 degrees clockwise and came to final rest in the outboard lane headed southwest. Skid to stop speed was calculated at 85.8 km/h (53.3 mph) assuming a friction coefficient of .75.



Figure 5. Pre-impact skid marks from the Toyota Camry.

Vehicle Damage

This impact sequence resulted in direct contact damage to the Camry that began at the front right bumper corner and extended an estimated 30 cm (12 in) left. Crush was minimal and was estimated at a maximum

of 5 cm (2 in) at the front right bumper corner. The crush under represented the energy absorbed by the Camry due to rebound of the bumper fascia and the front bumper's energy absorption system. The damage resulted in a 12 o'clock direction of force with an estimated Collision Deformation Classification (CDC) of 12-FRLW-1 from police and insurance photographs. Estimated delta V for this impact was 11-16 km/h (7-10 mph). Exterior damaged components consisted of the front bumper fascia, grille assembly, hood, radiator support, and right fender.



Figure 6. Crush damage sustained by the Camry.

Interior damage to the Camry consisted of a displaced rearview mirror, fractured windshield, and unspecified damage to the right sunvisor resultant of contact with the front right air bag. The normal deployment path of the air bag was restricted by the infant seat positioned in the front right seated position and the air bag subsequently deployed upward which displaced the rearview mirror and fractured the windshield.



Figure 7. Crush damage sustained by the back left bumper of the Celica.

The Celica sustained direct damage from its impact with the frontal plane of the Camry that began at the back left bumper corner and extended approximately 30 cm (12 in) right. Maximum crush was located at the back left bumper corner and was estimated at 10 cm (4 in). The damage resulted in a 6 o'clock direction of force and an estimated CDC of 06-BLLW-1 from police and insurance photographs. Estimated Delta V for this impact was 16-19 km/h(10-12 mph). Exterior damaged components consisted of the back bumper fascia, left rear quarter panel, and liftback.

Infant Seat

The infant seat was a SmartFIT model manufactured by Century Products Company. The infant seat was designed for independent use in the vehicle or fitted into a base that was designed to be stationary in the vehicle. The infant seat was equipped with a level indicator on its right side which indicated the maximum safe recline position of the infant seat. The infant seat was also equipped with a canopy and pivoting carrying handle. Warning labels on the infant seat and an exemplar base identified the risks associated with rear

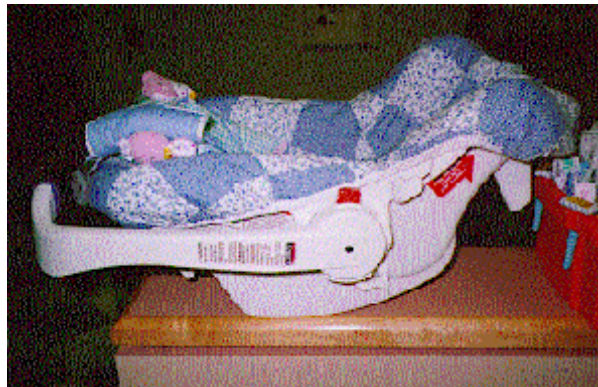

Figure 8. SmartFIT infant seat without the base.

facing infant seats and air bags. The driver of the Camry indicated that the infant seat did not sustain damage from the crash events with exception for the canopy which was displaced from the infant seat. Police photographs confirmed the driver's recollection of infant seat damage and showed a dislodged metal locking clip on the front right seat cushion. The driver also noted that the canopy was stowed against the back of the infant seat at the time of the crash and that its fabric was not torn, abraded, or burned. Police photographs identified that there were no abrasions to the shell of the infant seat.



Figure 9. Exemplar SmartFIT infant seat with base.

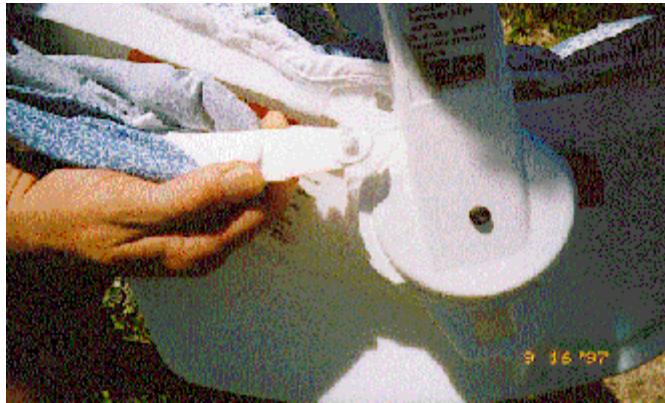

Figure 10. Attachment point of the dislodged infant seat canopy.

Aftermarket Equipment

A police photograph (Figure 11) indicated that the available front right 3-point manual lap and shoulder belt was equipped with an aftermarket shoulder belt webbing adjuster. It was yellow in color and displayed the word SAFEFIT. The driver of the vehicle indicated that it was used to comfortably adjust the 3-point manual lap and shoulder belt for a five year old child. The belt was equipped with the device at the time it was looped through the infant seat.



Figure 11. View of the right front seat with the webbing's SAFEFIT device, displaced infant seat canopy, and metal locking clip.



Figure 12. Utilized exemplar SAFEFIT device.

Restraint of the Male Infant Passenger

The driver of the vehicle stated that the male infant was consistently placed in the infant seat when traveling in the vehicle and that it was normally positioned in the rear seat, however, the infant had been upset on the day of the crash and the driver subsequently positioned the child with the infant seat in the front right position. Although the driver indicated that the infant seat's base was utilized with the infant seat in the front right seated position on the crash date, the investigating police officer recalled that the base was not available in the vehicle or at the crash scene prior to departure of the driver and male infant passenger. It was, therefore, determined that the base was not used during this crash. The infant seat's belt slots were located on both sides of the seat adjacent to the junction of its carrying handle and shell. The lap and torso belt webbing was maneuvered into the belt slots and the SAFEFIT device positioned over the infant's lower body. The child was restrained in the infant seat by the 3-point harness system. The harness webbing was woven through the upper slots in the foam padding and shell of the infant seat.



Figure 13. Right lateral view of the Camry's passenger compartment and post-crash positioned infant seat.

Automatic Restraint System

The Supplemental Restraint System of the Camry consisted of a front left and front right air bag. The front left air bag was concealed within a four-spoke steering wheel rim and deployed from H-configuration module cover flaps. It was unknown if the air bag was tethered or was equipped with vent ports. The front right air bag deployed from a mid mount module assembly that was incorporated in the right instrument panel. Insurance and police photographs show that there was at least one vent port located on the left side of the bag (with respect to the vehicle). It was unknown if the air bag consisted of other vent ports. A police photograph (Figure 14) that illustrated the rearward excursion of the front right air bag indicated the lack of tethers.



Figure 14. Right lateral view of the Camry's passenger compartment with rear facing infant seat and front right air bag excursion.

Driver Injuries

Injury	Injury Severity (AIS-90)	Injury Mechanism
Anterior right forearm abrasion	Minor (790202.1,1)	Front left air bag
Left shoulder sprain	Minor (751020.1,2)	3 -point manual lap and shoulder belt

Driver Kinematics

The driver of the Camry was a 31 year old female driver who had a stated height of 178 cm (70 in) and weight of 59 kg (129 lbs). The Police Crash Report (PCR) and the driver indicated that she was restrained by the manual lap and shoulder belt. The driver stated that the seat track was two or three notches forward of the full back position. There was no evidence of occupant contact in police or insurance photographs. At impact, the driver responded to the 12 o'clock direction of force and loaded the shoulder belt webbing which was locked by the inertia activated retractor. Her loading force against the belt webbing resulted in left shoulder strain (AIS-1). The driver's right hand was probably on the steering wheel rim at the time of the crash and the deploying air bag contacted the right forearm which resulted in an anterior right forearm abrasion (AIS-1). She was transported from the scene of the crash to a local hospital via private vehicle where she received treatment for sustained injuries.

Infant Injuries

Injuries	Injury Severity (AIS-90)	Injury Mechanism
Bilateral subdural hemorrhage	Critical (140654.5,3)	Front right air bag
Hemorrhagic cortical contusions	Serious (140614.3,2)	Front right air bag
Subarachnoid hemorrhage	Serious (140684.3,9)	Front right air bag
Closed head injury (unknown loss of consciousness)	Moderate (160699.2,0)	Front right air bag
Right superior and posterior parietal calvarial fractures	Moderate (150400.2,1)	Front right air bag
Right scalp hematoma	Minor (190402.1,1)	Front right air bag

Infant Kinematics

The 3 month old male infant passenger had a reported (driver of the vehicle) weight of 5.4 kilograms (12.0 lbs) and length of 61 cm (24 in) at the time of the crash. He was restrained by an integral 3-point harness in the rear facing infant seat which was secured by the available 3-point manual lap and shoulder belt system to the front right passenger seat. Had the infant seat not been secured in the front right seated position, the infant seat would have been displaced forward, against the front right air bag module cover flap as it opened to deploy the air bag, due to 21.3 meters (70 feet) of heavy pre-impact braking. This scenario is not consistent with the lack of damage to the shell of the infant seat. The seat track was positioned approximately three notches forward of the full back position. At impact, the infant seat was probably within the outer limits of the deploying air bag and restricted its rearward excursion path. The rear aspect and canopy of the infant seat was contacted by the deploying air bag which dislodged the canopy from the infant seat and resulted in its rearward displacement. The expansion of the air bag against the infant seat accelerated the seat in a rearward direction. As a result of bag contact against the restraint, the child sustained bilateral subdural hemorrhage (AIS-5), hemorrhagic cortical contusions (AIS-3), subarachnoid hemorrhage (AIS-3), closed head injury (AIS-2), right superior and posterior parietal calvarial fractures (AIS-2), and a right scalp hematoma (AIS-1). The position of the rear facing infant seat restricted the air bag's normal deployment path which resulted in the upward displacement of the bag. The air bag contacted and dislodged the Camry's rearview mirror, fractured the windshield glazing, and generated unspecified damage to the right sunvisor.

Medical Treatment

The male infant passenger was alert and oriented post-crash and was crying. His mother, the driver of the Camry, removed him from the vehicle while he remained in the infant seat and awaited assistance. Although emergency medical personnel responded to the crash scene, they did not treat the infant, but suggested that he be taken to a local hospital to be evaluated. The driver's husband, who worked approximately two miles from the crash scene, responded to the scene and transported the infant and driver via private vehicle to a nearby hospital for treatment. During transport, a right scalp hematoma was discovered and breathing difficulties commenced. The infant was evaluated at the local hospital and subsequently transferred to a trauma center due to the severity of the injuries. The male infant was treated and stabilized in the emergency room of the trauma center and subsequently hospitalized for eleven days of observation. He has since recovered from the injuries sustained in the crash and has not experienced developmental difficulties.