

Remote Investigation / Vehicle to Vehicle
Dynamic Science, Inc. / Case Number: DS98014
1994 Plymouth Voyager
Kentucky
March 1996

This document is disseminated under the sponsorship of the Department of Transportation in the interest of information exchange. The United States Government assumes no responsibility for the contents or use thereof.

The opinions, findings, and conclusions expressed in this publication are those of the authors and not necessarily those of the National Highway Traffic Safety Administration.

The crash investigation process is an inexact science which requires that physical evidence such as skid marks, vehicular damage measurements, and occupant contact points be coupled with the investigator's expert knowledge and experience of vehicle dynamics and occupant kinematics in order to determine the pre-crash, crash, and post-crash movements of involved vehicles and occupants.

Because each crash is a unique sequence of events, generalized conclusions cannot be made concerning the crashworthiness performance of the involved vehicle(s) or their safety systems.

| | | | | | |
|---|--|--------------------------------------|----------------------------|---|-----------|
| 1. Report No. DS98014 | | 2. Government Accession No. | | 3. Recipient Catalog No. | |
| 4. Title and Subtitle In-Depth Accident Investigation | | | | 5. Report Date | |
| | | | | 6. Performing Organization Report No. | |
| 7. Author(s) Dynamic Science, Inc. | | | | 8. Performing Organization Report No. | |
| 9. Performing Organization name and Address Dynamic Science, Inc. 530 College Parkway, Ste. K Annapolis, MD 21401 | | | | 10. Work Unit No. (TRAIS) | |
| | | | | 11. Contract or Grant no. DTNH22-94-D-27058 | |
| 12. Sponsoring Agency Name and Address U.S. Dept. of Transportation (NRD-32) National Highway Traffic Safety Administration 400 7th Street, SW Washington, DC 20590 | | | | 13. Type of report and period Covered [Report Month, Year] | |
| | | | | 14. Sponsoring Agency Code | |
| 15. Supplemental Notes | | | | | |
| 16. Abstract Vehicle 1, a 1994 Plymouth Voyager van driven by a pregnant 28-year-old female, was traveling eastbound on a state highway at a speed reported to be between 56-72 km/h (35-45 MPH). The front right of Vehicle 1 was occupied by an unrestrained 4-year-old (30 kg) female. The left rear was occupied by a 7-year-old female. The driver of Vehicle 1 stated that vehicles in front of her had stopped and she tried to avoid them by steering to the right and leaving the roadway. There is no explicit statement indicating that the driver braked, but this seems likely given the collision type. After leaving the roadway Vehicle 1 struck a power pole. A CDC-only barrier run produced a longitudinal delta v of -14.8 km/h (-9.2 mph). Both air bags deployed at this point. In other reports the driver indicated that she was trying to place the right front occupant back into her restraint when she ran off the road. The front right occupant was found by the driver under the deployed air bag. She was removed from the vehicle apparently by the driver and taken to a nearby house. Ambulance personnel found the child lying on the floor of the house. They noted a hematoma to the frontal region of her head and swelling of the right eye. She was immobilized and transported from the scene by ground ambulance. This occupant has a history of focal seizure disorder. She arrived at the hospital with a Glasgow Coma Scale of 3. She sustained contiguous abrasions to her face, cheeks, and forehead, as well as a laceration to the right eyelid. The abrasions were primarily on the right side of the face. There was some swelling of the forehead and a right peri-orbital edema. A CT scan revealed a subarachnoid hemorrhage in the basal cisterns with several small punctate contusions scattered throughout the hemispheres. There was also some cerebral edema, worse on right than the left. The child died the day after the crash. The cause of death is stated as cerebral edema with brain herniation. The child's body was later exhumed and a post-mortem examination was undertaken. This examination indicated that the child sustained a displaced C1/C2 cervical spinal injury and a blunt force cutaneous injury of the face and scalp. The driver of Vehicle 1 sustained several broken teeth and complained of pain to her left forearm. She was able to exit the vehicle on her own. This occupant was six months along in her pregnancy at the time of the crash. The left rear occupant was able to exit the vehicle on her own and walked to a nearby house. She sustained an abrasion to her forehead. | | | | | |
| 17. Key Words Air bag, deployment, injury, accident, fatality, passenger, | | | 18. Distribution Statement | | |
| 19. Security Classif. (of this report) | | 20. Security Classif. (of this page) | | 21. No of pages | 22. Price |

Dynamic Science, Inc.
Accident Investigation
Case Number: DS98014

TABLE OF CONTENTS

Background 1
 Description 1
 Investigation Type 1
 Crash Location 1
 Crash Date 1
 Notification Date 1
 Field Work Completed 1

Summary 1

Scene Diagram 3

Detailed Information 4
 Vehicles 4
 Occupants 5

Injuries and Injury Mechanisms 6

Occupant Kinematics 8

Photo Index 9

BACKGROUND:

Description: This case is being initiated in response to a report of an air bag related child fatality. The crash occurred in March 1996 at 1200 hours in Kentucky. NHTSA was advised of the case via the attorney for the driver of the case vehicle.

Investigation Type: Remote

Crash Location: Kentucky

Crash Date: March 1996

Notification Date: April 1998

Field Work Completed: September 1998

SUMMARY:

Vehicle 1, a 1994 Plymouth Voyager van driven by a pregnant 28-year-old female, was traveling eastbound on a state highway at a speed reported to be between 56-72 km/h (35-45 MPH). The front right of Vehicle 1 was occupied by an unrestrained 4-year-old (30 kg) female. The left rear was occupied by a 7-year-old female. The driver of Vehicle 1 stated that vehicles in front of her had stopped and she tried to avoid them by steering to the right and leaving the roadway.



Figure 1. Exterior, Vehicle 1

There is no explicit statement indicating that the driver braked, but this seems likely given the collision type. After leaving the roadway Vehicle 1 struck a power pole. A CDC-only barrier run produced a longitudinal delta v of -14.8 km/h (-9.2 mph). Both air bags deployed at this point. In other reports the driver indicated that she was trying to place the right front occupant back into her restraint when she ran off the road.

The front right occupant was found by the driver under the deployed air bag. She was removed from the vehicle apparently by the driver and taken to a nearby house. Ambulance personnel found the child lying on the floor of the house. They noted a hematoma to the frontal region of her head and swelling of the right eye. She was immobilized and transported from the scene by ground ambulance. This occupant has a history of focal seizure disorder. She arrived at the hospital with a Glasgow Coma Scale of 3. She sustained contiguous abrasions to her face, cheeks, and forehead, as well as a

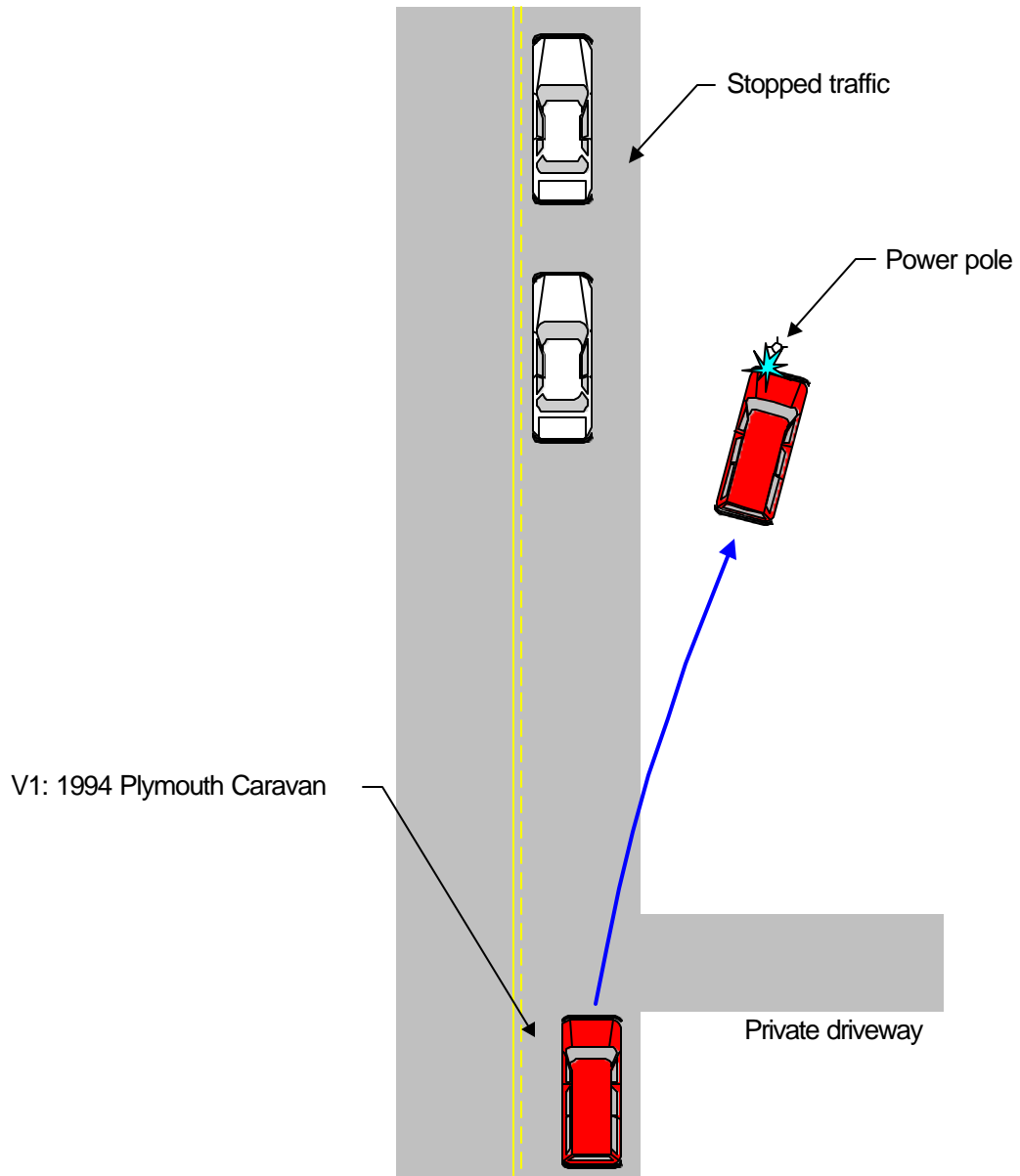
laceration to the right eyelid. The abrasions were primarily on the right side of the face. There was some swelling of the forehead and a right peri-orbital edema. A CT scan revealed a subarachnoid hemorrhage in the basal cisterns with several small punctate contusions scattered throughout the hemispheres. There was also some cerebral edema, worse on right than the left. The child died the day after the crash. The cause of death is stated as cerebral edema with brain herniation. The child's body was later exhumed and a post-mortem examination was undertaken. This examination indicated that the child sustained a displaced C1/C2 cervical spinal injury and a blunt force cutaneous injury of the face and scalp.

The driver of Vehicle 1 sustained several broken teeth and complained of pain to her left forearm. She was able to exit the vehicle on her own. This occupant was six months along in her pregnancy at the time of the crash. The left rear occupant was able to exit the vehicle on her own and walked to a nearby house. She sustained an abrasion to her forehead.


A chronology of events related to the crash is shown below:

| <u>Day 1 Event</u> | <u>Time</u> |
|--------------------------|-------------|
| Crash | 1200 |
| Ambulance dispatch | 1206 |
| Police notified | 1208 |
| Ambulance arrived | 1216 |
| Police arrived | 1218 |
| Ambulance departed scene | 1226 |
| Ambulance arrived @ ER | 1237 |
| Police cleared scene | 1250 |
| Transfer | 2305 |
| | |
| <u>Day 2 Event</u> | <u>Time</u> |
| Declared brain dead | 1500 |

Scene Diagram



DS9814



Not to scale

DETAILED INFORMATION**Vehicles**Vehicle 1

| | | |
|---------------------|--|-----------------------|
| Description: | 1994 Plymouth Voyager | |
| VIN: | 2P4GH253XRRXXXXXX | |
| Odometer: | Unknown | |
| Engine: | 3.0 l MPI | |
| Reported Defects: | None | |
| Cargo: | Unknown | |
| Damage Description: | Minor crush damage to left bumper and grille area. | |
| CDC: | 12FLEN1 | |
| Delta V: | Total | 14.8 km/h (9.2 mph) |
| | Longitudinal | -14.9 km/h (-9.2 mph) |
| | Latitudinal | 0 km/h (0 mph) |
| | Energy | 13,343 joules |



Figure 2. Exterior, Vehicle 1

(9,864 ft-lbs)

Occupants

| <u>Vehicle 1</u> | Occupant 1 | Occupant 2 | Occupant 3 |
|---------------------------------|------------------------------------|-----------------------------------|-------------------------|
| Age/Sex: | 28/Female | 4/Female | 7/Female |
| Seated Position: | Front left | Front right | Rear left |
| Seat Type: | Pedestal | Pedestal | Bench with folding back |
| Height: | Unknown | 102 cm (40 in.) | Unknown |
| Weight: | Unknown | 16 kg (35 lbs.) | Unknown |
| Occupation: | Unknown | NA | NA |
| Pre-existing Medical Condition: | Unknown | History of focal seizure disorder | Diabetic |
| Alcohol/Drug Involvement: | None | NA | NA |
| Driving Experience: | Presumed to be > 10 years | NA | NA |
| Body Posture: | Unknown | Unknown | Unknown |
| Hand Position: | Unknown | Unknown | Unknown |
| Foot Position: | Right foot presumed to be on brake | Unknown | Unknown |
| Restraint Usage: | Lap and shoulder used | None | Lap and shoulder used |
| Air bag: | Deployed | Deployed | NA |

Injuries and Injury Mechanisms

Vehicle 1

| | <u>INJURY</u> | <u>OIC CODE</u> | <u>ICD-9</u> | <u>SOURCE</u> |
|--------------|--|--------------------------|----------------|---------------|
| Driver: | Broken teeth | 251404.1,8 | 873.63 | Unknown |
| RF Occupant: | Diffuse axial injury | 140628.5,9 | -- | Windshield |
| | Loss of consciousness | 160824.5,0 | 850.5 | Windshield |
| | Subarachnoid hemorrhage | 140684.3,9 | 852.00 | Windshield |
| | Cerebral edema | 140668.3,1 | 852.00 | Windshield |
| | Cerebral edema | 140668.3,2 | 852.00 | Windshield |
| | Bilateral cerebral contusions | 140620.3,3 | 850.16 | Windshield |
| | Cerebral edema with subarachnoid hemorrhage | 140684.3,9 | 852.00 | Windshield |
| | Displaced C1/C2 cervical spinal injury | 650206.3,6 | 806.00 | Air bag |
| | Abrasion, right malar face, right periorbital face into forehead | 290202.1,1 290202.1,7 | 910.0 910.0 | Air bag |
| | Laceration, right eyelid | 297600.1,1 | 870.0 | Air bag |
| | Hematoma, extends from left frontal scalp to the left temporal scalp, terminating in the posterior left parietal scalp | 190402.1,2 | 920.0 | Windshield |
| LR Occupant: | Abrasion to forehead | 290202.1,7 | 910.0 | Unknown |

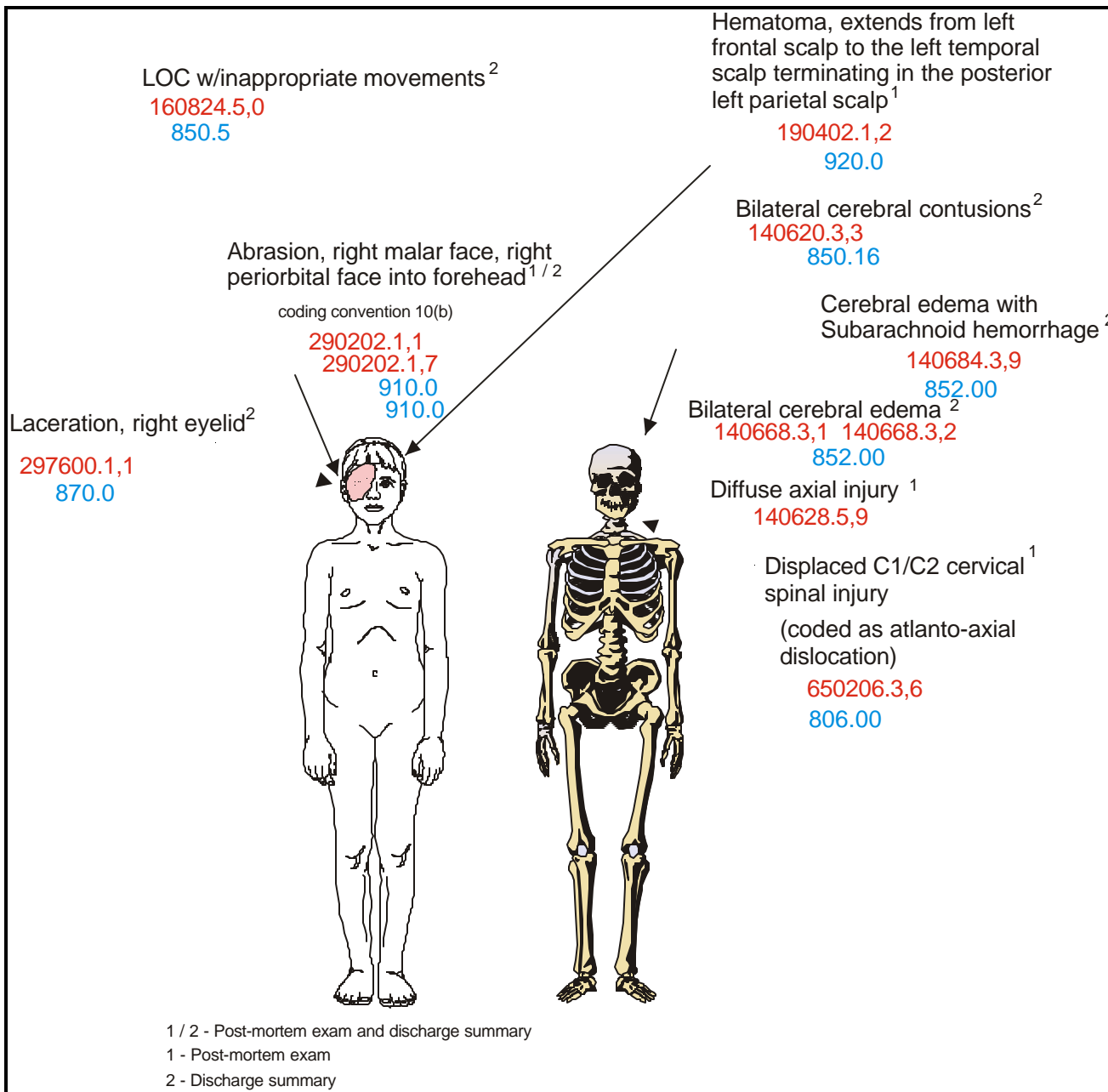


Figure 3. Front right occupant injuries

Occupant Kinematics

The front right occupant appears to have been seated in a forward facing fashion. She was unrestrained. In one report there is an indication that she was restrained at one time, but had gotten out of the restraints. As Vehicle 1 departed the roadway and the driver braked, this occupant was pitched forward with the right side of her face in a downward position. At impact, the air bag deployed and struck this occupant on the right side of her face. She was lifted upward and the left side of her head struck the windshield. The impact with the windshield likely caused the brain injuries. The combination of the air bag on one side and the windshield on the other likely caused the C1/C2 injury. Post impact, this occupant was found on the floor of the vehicle.

