

On-scene Air Bag Related Child Passenger Fatality  
Dynamic Science, Inc. / Case Number: DS98025  
1995 Geo Prizm 4-door  
California  
September 1998

---

*This document is disseminated under the sponsorship of the Department of Transportation in the interest of information exchange. The United States Government assumes no responsibility for the contents or use thereof.*

*The opinions, findings, and conclusions expressed in this publication are those of the authors and not necessarily those of the National Highway Traffic Safety Administration.*

*The crash investigation process is an inexact science which requires that physical evidence such as skid marks, vehicular damage measurements, and occupant contact points be coupled with the investigator's expert knowledge and experience of vehicle dynamics and occupant kinematics in order to determine the pre-crash, crash, and post-crash movements of involved vehicles and occupants.*

*Because each crash is a unique sequence of events, generalized conclusions cannot be made concerning the crashworthiness performance of the involved vehicle(s) or their safety systems.*

---

**Technical Report Documentation Page**

1. Report No. DS98025		2. Government Accession No.		3. Recipient Catalog No.	
4. Title and Subtitle In-Depth Accident Investigation				5. Report Date	
				6. Performing Organization Report No.	
7. Author(s) Dynamic Science, Inc.				8. Performing Organization Report No.	
9. Performing Organization name and Address Dynamic Science, Inc. 530 College Parkway, Ste. K Annapolis, MD 21401				10. Work Unit No. (TRAIS)	
				11. Contract or Grant no. DTNH22-94-D-27058	
12. Sponsoring Agency Name and Address U.S. Dept. of Transportation (NRD-32) National Highway Traffic Safety Administration 400 7th Street, SW Washington, DC 20590				13. Type of report and period Covered [Report Month, Year]	
				14. Sponsoring Agency Code	
15. Supplemental Notes					
16. Abstract  <p>The case vehicle, a 1995 Geo Prizm 4-door driven by a 32-year-old female (165 cm-65 in/56.7 kg-125 lb), was traveling southbound in the far left lane and traveling at a speed calculated by police to be between 48 km/h (30 mph) and 53 km/h (33 mph). The case vehicle was approaching stopped vehicles. The front right seat of the case vehicle was occupied by a 2-year-old male child (94 cm-37 in/18 kg-40 lbs) who was seated in a forward facing child seat. The child seat was identified as an Evenflo Champion/Scout/Trooper Convertible Child Seat with a Series Adjust-A-Shield. The child seat was in the possession of the police agency, and was not inspected. The other vehicle, a 1992 Chevrolet Corvette driven by a 29-year-old male, was braking to a stop behind the third vehicle, and directly in front of the case vehicle. A third vehicle, a 1998 Chevrolet Corvette driven by a 45-year-old male, was completely stopped at the intersection directly in front of the second other vehicle (1998 Corvette). The case vehicle was approaching stopped traffic; the other vehicle and the third vehicle were both stopped directly in front of the case vehicle for the red traffic signal. The driver of the case vehicle reported problems with the vehicle's brakes, but the mechanical inspection conducted by the police of the brake system "did not reveal any preexisting mechanical deficiencies that could have affected the normal functional ability of the vehicle upon the highway." The driver of the case vehicle also indicated that the 2-year-old was just falling asleep and she was attending to him. This was probably why the driver of the case vehicle did not see that traffic in front of her had come to a stop. She probably looked up and applied the brakes sharply. The case vehicle deposited approximately 16.9 meters (55.5 feet) of front right locked wheel skidmark. The driver of the case vehicle was unable to stop the vehicle and the front of case vehicle struck the back of the other vehicle. On impact both of the air bags in the case vehicle deployed. This collision pushed the other vehicle forward and the front of other vehicle struck the back of the third vehicle.</p> <p>The case vehicle sustained moderate damage to its front end. A CDC of 12FYEW1 was assigned to the damage. The case vehicle sustained 61 cm (24.0 in.) of direct damage that began at the front left bumper corner. It sustained a maximum crush was 21.7 cm (8.5 in.) at C<sub>3</sub>. WinSmash calculated a total delta V of 19.6 km/h (12.2 mph), a longitudinal delta V of -19.6 km/h (-12.2 mph), and a lateral delta V of 0.0 km/h (0.0 mph) for the case vehicle and a total delta V of 14.1 km/h (8.7 mph), a longitudinal delta V of 14.1 km/h (8.7 mph), and a lateral delta V of 0.0 km/h (0.0 mph) for the other vehicle. The results fit the collision model and appear reasonable. The case vehicle was towed from the scene.</p> <p>The 2-year-old in the case vehicle sustained fatal injuries as a result of interaction with the front right passenger's airbag. An invasive autopsy was performed one day after the 2-year-old expired. The coroner ruled the cause of death to be the transection of the spinal cord with fracture due to blunt force trauma.</p>					
17. Key Words Airbag, deployment, injury, fatality, passenger, child, child seat			18. Distribution Statement		
19. Security Classif. (of this report)	20. Security Classif. (of this page)	21. No of pages	22. Price		

**Dynamic Science, Inc.**  
**Accident Investigation**  
**Case Number: DS98025**

**TABLE OF CONTENTS**

BACKGROUND ..... 1  
    Description ..... 1  
    Investigation Type ..... 1  
    Crash Location ..... 1  
    Crash Date ..... 1  
    Notification Date ..... 1  
    Field Work Completed ..... 1

SUMMARY ..... 1

Forward Facing Child Seat Discussion ..... 5

Scene Diagram- Scene Evidence ..... 8  
    Scene Diagram- Impact ..... 9

DETAILED INFORMATION ..... 10  
    Vehicles ..... 10  
    Occupants ..... 13  
    Injuries and Injury Mechanisms ..... 16  
    Occupant Kinematics ..... 19

**BACKGROUND:**

**Description:** This case was initiated in response to a report of fatal injuries sustained by the front right occupant, a 2-year-old male child in a forward facing child restraint. The fatal injuries were caused by the deployment of the front right passenger's air bag. This case was conducted as an on scene investigation. The NHTSA notified DSI on September 24, 1998 as a result of several newspaper articles. The case vehicle was inspected close to six months after the date of the collision at a vehicle storage facility where the vehicle was being stored by the attorney representing the driver of the case vehicle. Present at the inspection were the attorney representing the driver of the case vehicle, and an engineer who also inspected the case vehicle. Prior to the case vehicle's inspection, the major crash investigation team for the state patrol had inspected the vehicle and were in possession of the child restraint and the case vehicle's front right lap and shoulder restraint.

**Investigation Type:** On-Scene  
**Crash Location:** California  
**Crash Date:** September, 1998  
**Notification Date:** September 24, 1998  
**Field Work Completed:** March, 1999

**SUMMARY:**

This collision occurred in the southbound lanes of a state route south of an intersection in an unincorporated city of southern California in September 1998 at 1323 hours. The state route is a north-south, two way, straight, level newly paved asphalt roadway. The roadway runs in a northwest, southeast manner. Southbound lanes consists of two lanes separated by broken white lines. There is a two-way left turn lane in the middle of the roadway. There were no visual obstructions noted or claimed, and the weather was warm and dry at the time of the collision. The roadway was dry and free of defects, and the speed limit at this location is 64 km/h (40 mph).



**Figure 1.** Scene of collision with vehicles at final rest.

The case vehicle, a 1995 Geo Prizm 4-door driven by a 32-year-old female (165 cm-65 in/56.7 kg-125 lb), was traveling southbound in the far left lane and traveling at a speed calculated by police to be

between 48 km/h (30 mph) and 53 km/h (33 mph). The case vehicle was approaching stopped vehicles. The front right seat of the case vehicle was occupied by a 2-year-old male child (94 cm-37 in/18 kg-40 lbs) who was seated in a forward facing child seat. The child seat was identified as an Evenflo Champion/Scout/Trooper Convertible Child Seat with a Series Adjust-A-Shield. The child seat was in the possession of the police agency, and was not inspected.

The other vehicle, a 1992 Chevrolet Corvette driven by a 29-year-old male, was braking to a stop behind the third vehicle, and directly in front of the case vehicle. A third vehicle, a 1998 Chevrolet Corvette driven by a 45-year-old male, was completely stopped at the intersection directly in front of the second other vehicle (1998 Corvette).

The case vehicle was approaching stopped traffic; the other vehicle and the third vehicle were both stopped directly in front of the case vehicle for the red traffic signal. The driver of the case vehicle reported problems with the vehicle's brakes<sup>1</sup>, but the mechanical inspection conducted by the police of



**Figure 2.** Exterior damage to case vehicle.

---

<sup>1</sup> The driver of the case vehicle had indicated to her husband the night before the crash that the brakes of the case vehicle were making a “weird noise” when she braked or turned corners. They decided to wait until the weekend to look at them since the braking efficiency was never affected. Prior to impact the driver of the case vehicle slowly pressed on the brake pedal to begin to slow. She said brake pedal “felt like it was chugging” and the brakes were making a squealing noise. She pumped the brake pedal twice and the vehicle felt like it was “jerking”. She then applied the brakes sharply and felt the car sliding. She did not

the brake system “did not reveal any preexisting mechanical deficiencies that could have affected the normal functional ability of the vehicle upon the highway.” The driver of the case vehicle also indicated that the 2-year-old was just falling asleep and she was attending to him. This was probably why the driver of the case vehicle did not see that traffic in front of her had come to a stop. She probably looked up and applied the brakes sharply. The case vehicle deposited approximately 16.9 meters (55.5 feet) of front right locked wheel skidmark. The driver of the case vehicle was unable to stop the vehicle and the front of case vehicle struck the back of the other vehicle. On impact both of the air bags in the case vehicle deployed. This collision pushed the other vehicle forward and the front of other vehicle struck the back of the third vehicle.

The case vehicle sustained moderate damage to its front end. A CDC of 12FYEW1 was assigned to the damage. The case vehicle sustained 61 cm (24.0 in.) of direct damage that began at the front left bumper corner. It sustained a maximum crush was 21.7 cm (8.5 in.) at C<sub>3</sub>. WinSmash<sup>2</sup> calculated a total delta V of 19.6 km/h (12.2 mph), a longitudinal delta V of -19.6 km/h (-12.2 mph), and a lateral delta V of 0.0 km/h (0.0 mph) for the case vehicle and a total delta V of 14.1 km/h (8.7 mph), a longitudinal delta V of 14.1 km/h (8.7 mph), and a lateral delta V of 0.0 km/h (0.0 mph) for the other vehicle. The results fit the collision model and appear reasonable. The case vehicle was towed from the scene.

The other vehicle sustained moderate damage to its rear end and minor damage to its front. It was driven from the scene by the driver. The third vehicle sustained minor damage to its rear end and was driven from the scene by the driver.

After the impact the driver of the case vehicle reported heavy smoke and she thought her vehicle was “going to blow up”. In concern for the 2-year-old child, she unbelted the child seat and grabbed him out of the child seat. She exited the vehicle out of the driver’s door. The driver of the third vehicle opened the case vehicle’s driver door and saw that it was filled with smoke. He saw the driver of the case vehicle reaching to the right and she then turned towards him and handed him the 2-year-old. The driver of the third vehicle saw that the 2-year-old was blue in the face and appeared not to be breathing. The driver of the third vehicle laid the 2-year-old and on the ground and began performing CPR. Another bystander came over, identified herself as a registered nurse, and took over giving mouth to mouth while the driver of the third vehicle began chest compressions. Fire department personnel and paramedics arrived on the scene and took over treatment of the 2-year-old.

The driver of the case vehicle reported injuries from the air bag consisting on two chipped front teeth (AIS 1), lacerations to her chin (AIS 1) and the inside of her mouth (AIS 1). She was treated at the scene by paramedics and transported to a local hospital where she received treatment and was released.

---

remember if the case vehicle ever slowed before impact.

<sup>2</sup> Calculated with WinSmash 1.2.1 using crush for the case vehicle and a CDC only for the other vehicle. Stiffness and size coefficients were calculated using an NCAP frontal barrier crash for the case vehicle.

The following table describes the time line from when the front right occupant in the case vehicle arrived at the initial hospital for treatment to when he expired.

Event	Time
Transported and arrived at first hospital	1354
Transferred to trauma center from first hospital	1430
Arrived at ER of trauma center	1500
Police arrived	1743
Admitted to pediatric intensive care unit of trauma center	1630
Expired	Three days later @ 1525

An invasive autopsy was performed one day after the 2-year-old expired. The following injuries are indicated on the autopsy report, and appear to be consistent with airbag contact; a complete transection of the upper cervical spinal cord (AIS 6) with fractures of the second (AIS 5) and fourth

(AIS 5) cervical vertebra with subdural and subarachnoid hemorrhages at the tip of the transected

region, a subdural (AIS 4) and minimal subarachnoid (AIS 3) hemorrhages to the dorsal surface that

was confined to the left side of the brain. There was the presence of subarachnoid hemorrhage at the

base of the brain. There was massive swelling of the brain (AIS 3). There was marked swelling of the neck with a large abrasion (AIS 1) erythema going from one side of the external ear to the other side across the entire anterior neck and base of the chin area. This abraded area measured 17.15 cm (6.75 in.) x 6.35cm (2.5 in.). There was the presence of an abrasion (AIS 1) on the left angle of the mouth and a contusion (AIS 1) on the lower lip. The tongue showed a bite (AIS 2) at the tip, with hemorrhage in the deep muscle area. Hospital records also indicated a cerebral edema (AIS 3). The coroner ruled the cause of death to be the transection of the spinal cord with fracture due to blunt force trauma.



**Figure 3.** Driver's air bag—case vehicle.

The police report indicated that neither the driver of the other vehicle or the third vehicle reported any injuries.



The case vehicle was equipped with driver's side and front right passenger's airbags. The driver's airbag was housed in the steering wheel hub and measured 59.0 cm (23.2 in.) in diameter. It had two vent ports and was not tethered. The dual module covers opened in a H-configuration and were not damaged. The maximum post deflated excursion measured 38.5 cm (15.2 in.). The driver's airbag had makeup transfer on the left-mid area. There were also black linear smudges that were probably module cover contacts, and a possible blood spot on the upper right area. The front right passenger's airbag is mid-mounted and housed within the instrument panel. It measured 50.0 cm (19.9 in.) by 51.0 cm (20.1 in.). It had two vent ports and was not tethered. The single hinged module cover appeared to have been contacted by the child seat. There was a 5.0 cm (2.0 in.) vertical white transfer near the left corner and appeared to be "warped". The front right passenger's airbag had black smudges on the right-center area and above the right vent port that were probably caused by contact with the module cover. The front right passenger airbag was also abraded about the front center. There was no evidence of skin transfer. The maximum post deflated excursion measured 55.0 cm (21.7 in.), and 39.5 cm (15.6 in.) from maximum excursion to the seat back.



Figure 5. Child seat.

The driver of the case vehicle was fully conscious, seated upright in a normal fashion, wearing the lap and shoulder belt, and her right foot on the brake pedal. She was seated in a cloth covered bucket type seat. The seat's exact position could not be determined since the police inspection as well as the attorney's inspection had moved the seat track and the seat back recline positions. At impact with the rear end of the other vehicle, the driver of the case vehicle went forward and up, engaging the deploying air bag with her face. She chipped two front teeth and sustained lacerations to her chin and the inside of her mouth.

#### Forward Facing Child Seat Discussion

As indicated earlier, the 2-year-old child was in the front right seat position of the case vehicle seated in a forward facing child seat that was identified as an Evenflo Champion/Scout/Trooper Convertible Child Seat with a Series Adjust-A-Shield model number 224144P1 and was manufactured on December 29, 1995. The manufacturer's instructions indicate that the child seat has two adjustment positions. The reclined position is for use with the child seat rear facing with infants



Figure 4. Front right passenger's air bag.

who weigh 2.2 kg (5 lbs) to 9 kg (20 lbs). Both the upright and reclined position may be used in forward facing position with toddlers weighing over 9 kg (20 lbs). There was one recall found for the child seat which stated that “toddler section of the instruction booklet labeled as being for infant use. This may cause consumers to believe infants under 9 kg (20 lbs) can ride forward facing.”

The child seat was in the possession of the police agency, and was never inspected by this investigator. The police did inspect the child seat and the following information was obtained from their report. The child seat was owned by the driver of the case vehicle since June 1996. The child seat was improperly anchored to the front right seat using the lap and shoulder belt. This was primarily because the child’s seat locking clip was not used with a sliding latch plate. It should be noted however that the case vehicle is equipped with switchable retractors from an emergency locking retractor (ELR) to an automatic locking retractor (ALR)<sup>3</sup>. A caution label on the front right seat indicates “... Before securing a forward-facing child restraint ALWAYS move the front passenger seat as far back as it will go. Then pull the safety belt out all the way to lock the belt, so you can use it with the forward-facing child restraint. Or, secure the child restraint in the rear seat.” Had the retractor been switched to the ALR position, the child’s seat locking clip would not have been required. The Police’s inspection of the ELR indicated that it was unremarkable indicating that it was more than likely not switched to the ALR position. The harness straps of the child seat were improperly looped through the middle positions. In a forward facing position (as the child seat was being used), the child seat harness straps should have been looped through the upper (top) positions for toddlers as is indicated in the child seat instructions.

The driver of the case vehicle stated to the police that she “strapped her son’s car seat into the car as usual. She slid the seatbelt through the back of the car seat and buckled the belt properly in the buckle. She put her son in the car seat and lowered the lap rest onto his lap. She clasped the buckle into the car seat from the lap rest. The plastic piece on the belts on the front of the seat was situated on his lower chest area, above his belly button. She normally put him in the back seat, but she was unable to attend to him when he was seated in the back.

The police report concluded that the case vehicle’s front right seat was adjusted to the rear most track position. The lap and shoulder belt was used to anchor the child seat to the vehicle’s seat. There was a 30.5 cm (12.0 in.) long section of material transfer on the inboard



**Figure 6.** Improper harness slotting.

side of the shoulder belt webbing and mild curling. This material transfer was ingrained into the webbing fabric and along the edges of the webbing and was deposited by the plastic shell of the child seat during

---

<sup>3</sup> The owner’s manual indicated that both front seat positions were equipped with switchable seat belt retractors; however, the driver’s side would not switch to ALR mode when it was inspected.

occupant loading. The length of the material transfers on the webbing that were deposited by the child seat supports the opinion that the restraint webbing was not sufficiently tightened. This was primarily as a result of not switching the front right seat belt retractor from ELR to ALR mode.

It is the opinion of the investigator that the 2-year-old child was seated on the front right seat position of the case vehicle in a forward facing child seat. The child was restrained by the child seat's harness with the harness tie improperly positioned above his belly. The child seat was improperly anchored to the vehicle's front right seat; primarily that the seat belt retractor was not switched from an ELR mode to ALR mode. The driver of the case vehicle did not see that traffic in front of her had come to a stop. She applied the brakes sharply. As a result of the pre-impact braking, the child seat traveled forward prior to the case vehicle striking the other vehicle. The child seat's improper installation caused the child seat to strike the lower instrument panel and the front right passenger's airbag module cover. There was

white transfer evidence on the lower right instrument panel area and similar colored transfer on the front right passenger's airbag module cover. The front right passenger's airbag module cover was also "warped". On impact with the rear end of the other vehicle, the front right passenger's airbag deployed. The front right passenger's airbag module cover probably struck the child seat; the police inspection of the child seat did not indicate any damage to the child seat. The deploying air bag came into contact with the anterior part of 2-year-old's neck and face. There was marked swelling of the neck with a large abrasion erythema going from one side of the external ear to the other side across the entire anterior neck and base of the chin area. This abraded area measures 17.15 cm (6.75 in.) x 6.35cm (2.5 in.). There was an abrasion on the left angle of the mouth and a contusion on the lower lip. The tongue showed a bite at the tip. As the air bag continued its unfolding pattern, the 2-year-old's head was rapidly accelerated rearward causing the fatal injuries of a complete transection of the upper cervical spinal cord with fractures of the second and fourth cervical vertebra with subdural and subarachnoid hemorrhages. The child came to final rest seated in the child seat.



**Figure 7.** Transfer from child seat.



**Figure 8.** Transfer from child seat.

Scene Diagram- Scene Evidence

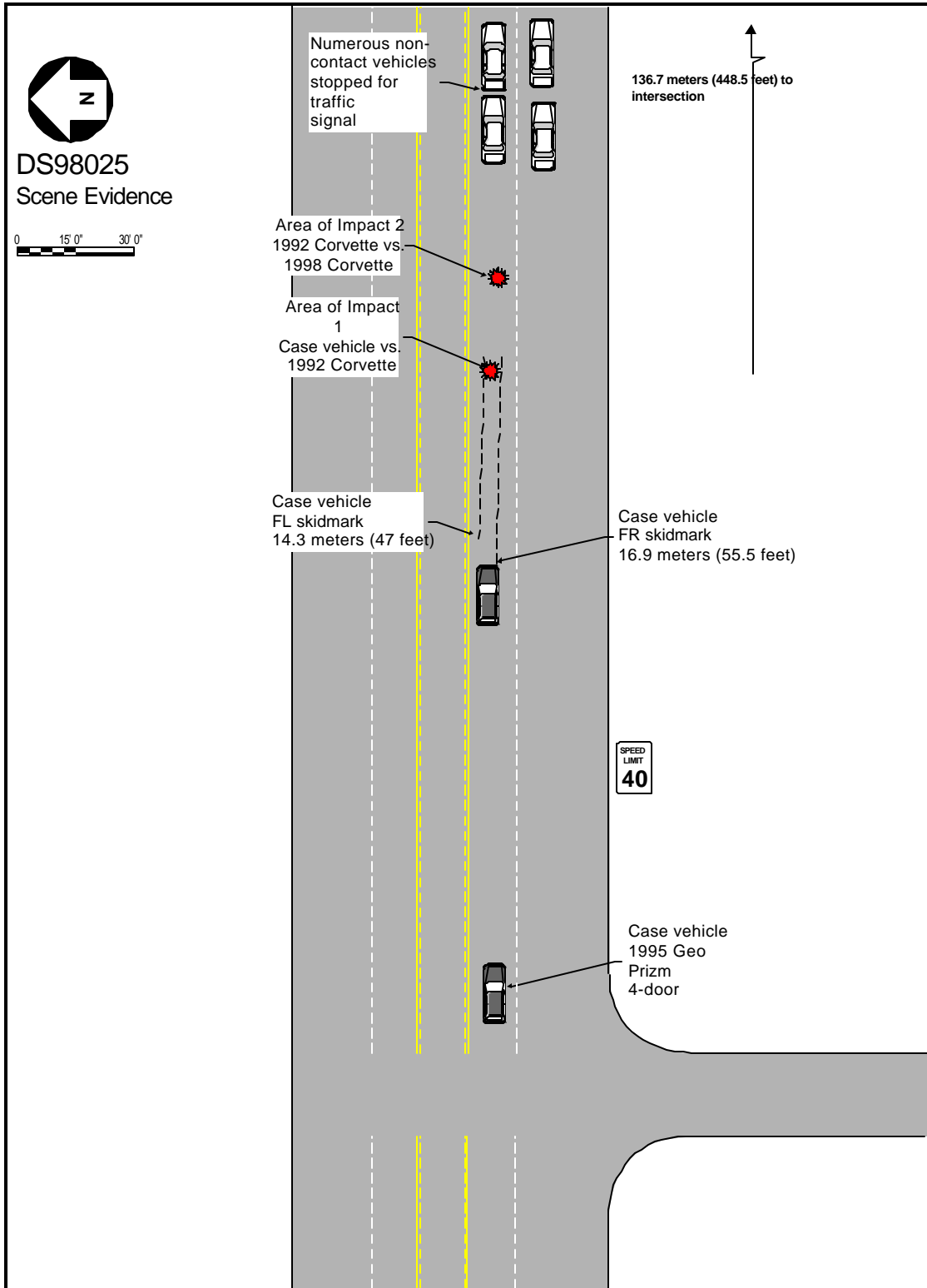


Figure 9. Scene diagram—evidence.

Scene Diagram- Impact

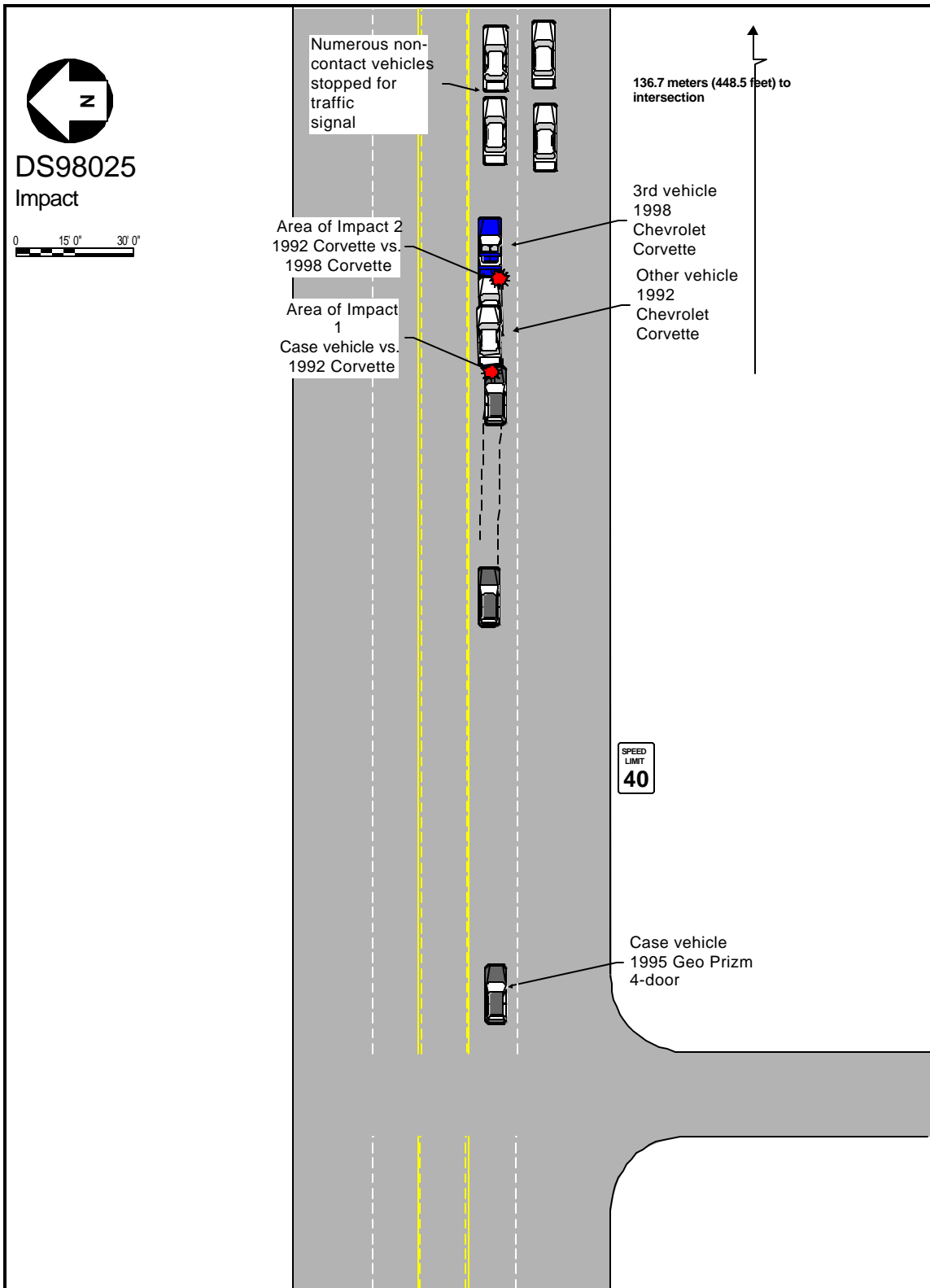


Figure 10. Scene diagram-impact.



**DETAILED INFORMATION****Vehicles**Case Vehicle

Description:	1995 Geo Prizm 4-door	
VIN:	1Y1SK5262SZXXXXXX	
Odometer:	79,297 kilometers (49,273 miles)	
Engine:	1.6 L V4	
Reported Defects:	None reported.	
Cargo:	None at vehicle inspection	
Damage Description:	Moderate damage to the front bumper, hood and grille area. The front left fender was induced outward.	
CDC:	12FYEW1	
Delta V:	Total	19.6 km/h ( 12.2 mph)
	Longitudinal	-19.6 km/h (-12.2 mph)
	Latitudinal	0.0 km/h ( 0.0 mph)
	Energy	21,025 joules (15,510 ft-lbs)



**Figure 11.** Exterior crush to case vehicle.

Other Vehicle

Description: 1992 Chevrolet Corvette  
 VIN: 1G1YY23P4N5XXXXXX  
 Odometer: Unknown  
 Engine: Unknown  
 Reported Defects: None noted on police report  
 Cargo: Unknown  
 Damage Description: Moderate damage to its rear end and minor damage to its front end. The rear end damage consisted of contact damage from the license plate towards the right side. The right rear quarter panel was cracked. There was minor damage to the front bumper consisting of a few nicks to the paint.

CDC (Estimated from police photographs):  
 Impact 1 - 06BZEW1  
 Impact 2 - 12FZEW1

Delta V (Impact 1 vs case vehicle):  
 (Impact 2 not calculated)

Total	14.1 km/h ( 8.7 mph)
Longitudinal	14.1 km/h ( 8.7 mph)
Latitudinal	0.0 km/h (0.0 mph)
Energy	10,706 joules ( 7,898 ft-lbs)



**Figure 12.** Exterior damage to other vehicle.

Third Vehicle

Description:	1998 Chevrolet Corvette	
VIN:	1G1YY22G4W5XXXXXX	
Odometer:	Unknown	
Engine:	Unknown	
Reported Defects:	None noted on police report	
Cargo:	Unknown	
Damage Description:	Minor damage to its rear end consisting of small scratches. No prior damage was noted or claimed.	
CDC (Estimated from police photographs):	Impact 2 - 06BZEW1	
Delta V (Not calculated):	Total	Unknown
	Longitudinal	Unknown
	Latitudinal	Unknown
	Energy	Unknown



**Figure 13.** Exterior damage to third vehicle.



**Occupants**

<u>Case Vehicle</u>	Occupant 1	Occupant 2
Age/Sex:	32/Female	2/Male
Seated Position:	Front left	Front right
Seat Type:	Cloth covered bucket seat, exact seat track position unknown due to inspection by several parties.	Cloth covered bucket seat, seat track position at rear most position per police report.
Height:	165 cm (65 in)	94 cm (37 in)
Weight:	57 kg (125 lb)	18 kg (40 lb)
Occupation:	Dental assistant	NA
Pre-existing Medical Condition:	None noted	None noted
Alcohol/Drug Involvement:	None	None
Driving Experience:	Assumed > 16 years	Unknown
Body Posture:	Assumed normal, upright.	Assumed normal, upright within the child restraint. Reported to have been falling asleep.
Hand Position:	Unknown, assumed both on steering wheel.	Unknown
Foot Position:	Right foot on brake pedal, left foot on floorboard	Unknown
Restraint Usage:	Lap and shoulder belt used	Lap and shoulder belt used with child restraint per police report
Airbag:	Steering wheel hub driver's airbag present and deployed as a result of impact.	Front right passenger's mid-mount-instrument panel airbag present and deployed as a result of impact.

<u>Other Vehicle</u>	Occupant 1
Age/Sex:	29/Male
Seated Position:	Front left
Seat Type:	Unknown
Height:	175 cm (69 in)
Weight:	73 kg (160 lbs)
Occupation:	Unknown
Pre-existing Medical Condition:	None noted
Alcohol/Drug Involvement:	None
Driving Experience:	Assumed > 9 years
Body Posture:	Assumed normal, upright
Hand Position:	Unknown
Foot Position:	Assumed right foot on brake pedal and left foot on floor board
Restraint Usage:	Lap and shoulder belts used—per police report
Air bag:	NA

<u>Third Vehicle</u>	Occupant 1
Age/Sex:	46/Male
Seated Position:	Front left
Seat Type:	Unknown
Height:	180 cm (71 in)
Weight:	90 kg (198 lbs)
Occupation:	Unknown
Pre-existing Medical Condition:	None noted
Alcohol/Drug Involvement:	None
Driving Experience:	Assumed > 26 years
Body Posture:	Assumed normal, upright
Hand Position:	Unknown
Foot Position:	Assumed right foot on brake pedal and left foot on floor board
Restraint Usage:	Lap and shoulder belts used—per police report
Air bag:	NA

**Injuries and Injury Mechanisms****Case Vehicle**

	<u>INJURY</u>	<u>OIC CODE</u>	<u>ICD-9</u>	<u>SOURCE</u>
Driver:	Two chipped front teeth	251404.1, 8	873.73	Air bag
	Lacerations to her chin and the inside of her mouth	290600.1, 8 243099.1, 8	873.49 873.60	Air bag
RF Occupant:	Fracture of the cervical second vertebra and fourth vertebra with a complete transection of the spinal cord with subdural and subarachnoid hemorrhage at tip of transection	640272.6, 6 640264.5, 6	806.1 806.01	Air bag
	Dorsal surface of the brain has subdural hemorrhage confined to the left side of the brain and minimal subarachnoid hemorrhage	140650.4, 2 140684.3, 2	852.25 852.05	Air bag
	Cerebral edema	140602.3, 0	348.5	Air bag
	Small contusional hemorrhage on the right side of the temporal cortex	140606.3, 1	853.0	Air bag
	Large abrasion erythema going from the one side of the external ear to the other side across the entire anterior neck and base of the chin area measuring (17.1 cm/6.75 in. X 6.4 cm/2.5 in.).	390202.1, 5	910.0	Air bag
	Abrasion on left angle of the mouth	290202.1, 2	910.0	Air bag
	Contusion on lower lip	290402.1, 8	920	Air bag

Tongue bite at tip of tongue with hemorrhage in the deep muscle area.	243404.2, 8	873.64	Air bag
---	-------------	--------	---------

**Other Vehicle**

INJURY

Driver: Not injured

**Third Vehicle**

INJURY

Driver: Not injured

## Occupant Kinematics

The driver of the case vehicle was fully conscious, seated upright in a normal fashion, wearing the lap and shoulder belt, and her right foot on the brake pedal. She was seated in a cloth covered bucket type seat. The seat's exact position could not be determined since the police inspection as well as the attorney's inspection had moved the seat track and the seat back recline positions. The driver of the case vehicle indicated that the 2-year-old was just falling asleep. The driver of the case vehicle did not see that traffic in front of her had come to a stop. She applied the brakes sharply. At impact with the rear end of the other vehicle, the driver of the case vehicle went forward and up, engaging the deploying airbag with her face. She chipped two front teeth and sustained lacerations to her chin and the inside of her mouth.

The 2-year-old child was seated on the front right seat position of the case vehicle in a forward facing child seat. The child was restrained by the child seat's harness with the harness tie improperly positioned above his belly as indicated by the driver of the case vehicle. The child seat was improperly anchored to the vehicle's front right seat. The seat belt retractor was not switched from ELR mode to ALR mode. As a result of the pre-impact braking, the child seat traveled forward prior to the case vehicle striking the second other vehicle. The child seat's improper installation, caused the child seat to move forward and strike the lower instrument panel and the front right passenger's airbag module cover.



There was white transfer evidence on the lower right instrument panel area and similar colored transfer on the front right passenger's airbag module cover. The front right airbag module cover was also "warped". On impact with the rear end of the other vehicle, the front right passenger's airbag deployed. The front right passenger's airbag module cover probably struck the child seat; the police inspection of the child seat did not indicate any damage to the child seat. The deploying airbag came into contact with the anterior part of 2-year-old's neck and face. There was marked swelling of the neck with a large abrasion erythema going from one side of the external ear to the other side across the entire anterior neck and base of the chin area. This abraded area measured 17.15 cm (6.75 in.) x 6.35cm (2.5 in.). There was an abrasion on the left angle of the mouth and a contusion on the lower lip. The tongue showed a bite at the tip. As the air bag continued its unfolding pattern, the 2-year-old's head was rapidly accelerated rearward causing the fatal injuries of a complete transection of the upper cervical spinal cord with fractures of the second and fourth cervical vertebra with subdural and subarachnoid hemorrhages. The child came to final rest seated in the child seat.

**Figure 14.** Child seat at scene—note forward position.