

On-scene Investigation / Vehicle to Vehicle
Dynamic Science, Inc. / Case Number: DS99018
1995 Ford Aspire
Washington
March 1999

This document is disseminated under the sponsorship of the Department of Transportation in the interest of information exchange. The United States Government assumes no responsibility for the contents or use thereof.

The opinions, findings, and conclusions expressed in this publication are those of the authors and not necessarily those of the National Highway Traffic Safety Administration.

The crash investigation process is an inexact science which requires that physical evidence such as skid marks, vehicular damage measurements, and occupant contact points be coupled with the investigator's expert knowledge and experience of vehicle dynamics and occupant kinematics in order to determine the pre-crash, crash, and post-crash movements of involved vehicles and occupants.

Because each crash is a unique sequence of events, generalized conclusions cannot be made concerning the crashworthiness performance of the involved vehicle(s) or their safety systems.

Technical Report Documentation Page

1. Report No. DS99018		2. Government Accession No.		3. Recipient Catalog No.	
4. Title and Subtitle In-Depth Accident Investigation				5. Report Date	
				6. Performing Organization Report No.	
7. Author(s) Dynamic Science, Inc.				8. Performing Organization Report No.	
9. Performing Organization name and Address Dynamic Science, Inc. 530 College Parkway, Ste. K Annapolis, MD 21401				10. Work Unit No. (TRAIS)	
				11. Contract or Grant no. DTNH22-94-D-27058	
12. Sponsoring Agency Name and Address U.S. Dept. of Transportation (NRD-32) National Highway Traffic Safety Administration 400 7th Street, SW Washington, DC 20590				13. Type of report and period Covered [Report Month, Year]	
				14. Sponsoring Agency Code	
15. Supplemental Notes					
16. Abstract <p>The case vehicle, a 1995 Ford Aspire 3-door hatchback driven by an unrestrained 40-year-old male, was traveling south on a two-lane gravel road approaching an uncontrolled four-leg intersection at a minimum travel speed of 24.6 km/h (15.3 mph). The driver's vision was obscured by frost and fogging of the windshield and the left front side glass. The front right seat position was occupied by a 5-year-old female (109 cm/43 in., 19.5 kg/ 43 lbs.). This seat position was equipped with a switchable lap and shoulder belt—which was not used—and a mid-mount passenger air bag. The air bag was covered by a curved, single flap module cover. At the time of the inspection, both front seats in the case vehicle were in the rearmost track position, but it seems likely that the seats had been moved prior to the inspection. The other vehicle, a 1983 Ford Ranger 4 x 2 regular cab pickup truck driven by a restrained 50-year-old male, was traveling westbound on a two-lane gravel road approaching the same intersection. Prior to entering the intersection, the driver of the case vehicle saw the other vehicle and began braking. The unrestrained front right occupant of the case vehicle slid forward toward the instrument panel. The front of the case vehicle (11FDEW1) struck the right A-pillar area of the other vehicle. The case vehicle sustained a longitudinal delta v of -16.2 km/h (-10.1 mph) and a lateral delta v of 5.9 km/h (3.7 mph). Both air bags in the case vehicle deployed at this point. The case vehicle was redirected in a clockwise rotation and came to rest facing southwest in the intersection. The other vehicle was redirected slightly in a counterclockwise direction and also came to rest west of the intersection. The front right occupant of the case vehicle sustained a contusion to the left side of her face, a right lower jaw fracture, a fracture of the left supraorbital plate, a subluxation injury at C1-C2, left and right focal temporal brain contusions, subarachnoid/subdural hemorrhage, and cerebral edema. The front right occupant survived for three days before expiring. Prior to impact, this occupant slid forward. The driver reported soreness to his left arm and leg. He was treated and later released from a local hospital. Both vehicles were towed from the scene due to damage and the case vehicle was later declared a total loss by the insurance company.</p>					
17. Key Words Air bag, deployment, injury, accident, fatality, passenger.			18. Distribution Statement		
19. Security Classif. (of this report)		20. Security Classif. (of this page)		21. No of pages	22. Price

Dynamic Science, Inc.
Accident Investigation
Case Number: DS99018

TABLE OF CONTENTS

Background	1
Description	1
Investigation Type	1
Crash Location	1
Crash Date	1
Notification Date	1
Field Work Completed	1
Summary	1
Scene Diagram	4
Detailed Information	6
Vehicles	6
Occupants	8
Injuries and Injury Mechanisms	10
Occupant Kinematics	11

BACKGROUND:

Description: This case was initiated in response to a report of an air bag deployment related child passenger fatality. This case was conducted as an on-scene investigation. The NHTSA was notified by the Washington State Police. DSI was notified on March 25, 1999.

Investigation Type: On scene

Crash Location: Washington

Crash Date: March, 1999

Notification Date: March 25, 1999

Field Work Completed: March 30, 1999

SUMMARY:

This crash occurred in Washington in March, 1999. This was an intersection type collision. The weather was clear and dry. Both intersecting roadways were gravel covered. The speed limit is 40 km/h (25 mph) for both roadways.

The case vehicle, a 1995 Ford Aspire 3-door hatchback driven by an unrestrained 40-year-old male, was traveling south on a two-lane gravel road approaching an uncontrolled four-leg intersection at a minimum travel speed of 24.6 km/h (15.3



Figure 1. Exterior, case vehicle

mph)¹. The driver's vision was obscured by frost and fogging of the windshield and the left front side glass. The front left seat position was equipped with an ELR-type lap and shoulder belt—which was not used—and a steering wheel mounted circular air bag. The air bag flap was covered by an H-configuration module cover. After the crash, the upper module cover flap had flipped toward the front of vehicle and became trapped behind the steering wheel rim. This air bag was equipped with two vents and two tethers. The front right seat position was occupied by a 5-year-old female (109 cm/43 in., 19.5 kg/43 lbs.). This seat position was equipped with a switchable² lap and shoulder belt—which was not used—and a deployed mid-mount passenger air bag. The air bag had vent ports at the 3 and 9 o'clock positions and did not have any tethers. The air bag was covered by a curved, single flap module cover.

At the time of the inspection, both front seats in the case vehicle were in the rearmost track position, but it seems likely that the seats had been moved prior to the inspection.

The other vehicle, a 1983 Ford Ranger 4 x 2 regular cab pickup truck driven by a restrained 50-year-old male, was traveling westbound on a two-lane gravel road approaching the same intersection.

Prior to entering the intersection, the driver of the case vehicle saw the other vehicle and began braking. The unrestrained front right occupant of the case vehicle slid forward toward the instrument panel. The front of the case vehicle (11FDEW1) struck the right A-pillar area of the other vehicle. The case vehicle sustained a longitudinal delta v of -16.2 km/h (-10.1 mph) and a lateral delta v of 5.9 km/h (3.7 mph). Both air bags in the case vehicle deployed at this point. The case vehicle was redirected in a clockwise rotation and came to rest facing southwest in the intersection. The other vehicle was redirected slightly in a counterclockwise direction and also came to rest west of the intersection.

1

Calculate skid speed

$$S = \sqrt{30 * D * f}$$

where D = distance in feet, f = coefficient of friction

$$S = \sqrt{(30 * 8 * 0.50)} = 10.95 \text{ mph}$$

Calculate combined speed using skid speed and total delta v

$$S = \sqrt{S^2(1) + S^2(2)} = 15.30 \text{ mph} = 24.6 \text{ km / h}$$

²Switchable from ELR mode to ALR mode

The front right occupant of the case vehicle sustained a contusion to the left side of her face, a right lower jaw fracture, a fracture of the left supraorbital plate, a subluxation injury at C1-C2, left and right focal temporal brain contusions, subarachnoid/subdural hemorrhage, and cerebral edema. The front right occupant survived for three days before expiring. Prior to impact, this occupant slid forward. Some part of her body (possibly her head) contacted the windshield, causing the star-pattern fracture. The occupant then rebounded. At impact, the occupant was forward of the seat and her head was nearly level with the instrument panel. As the air bag deployed, the right side of the air bag struck the left side of this occupant's face. The occupant's head was forced sharply to the right where it struck the side glass and the lower window frame. The plastic fascia covering the frame was broken and the side glass disintegrated. The investigating officer stated that he found hair from the occupant in the plastic fascia. The passenger air bag struck the right edge of the center mirror. The mirror rotated about its mounting bracket and struck and fractured the center portion of the windshield before being knocked off. There were no indications of any contact to the module cover.

The driver reported soreness to his left arm and leg. He was treated and later released from a local hospital.

Both vehicles were towed from the scene due to damage and the case vehicle was later declared a total loss by the insurance company.



Figure 2. Side glass broken by front right occupant

Scene Diagram

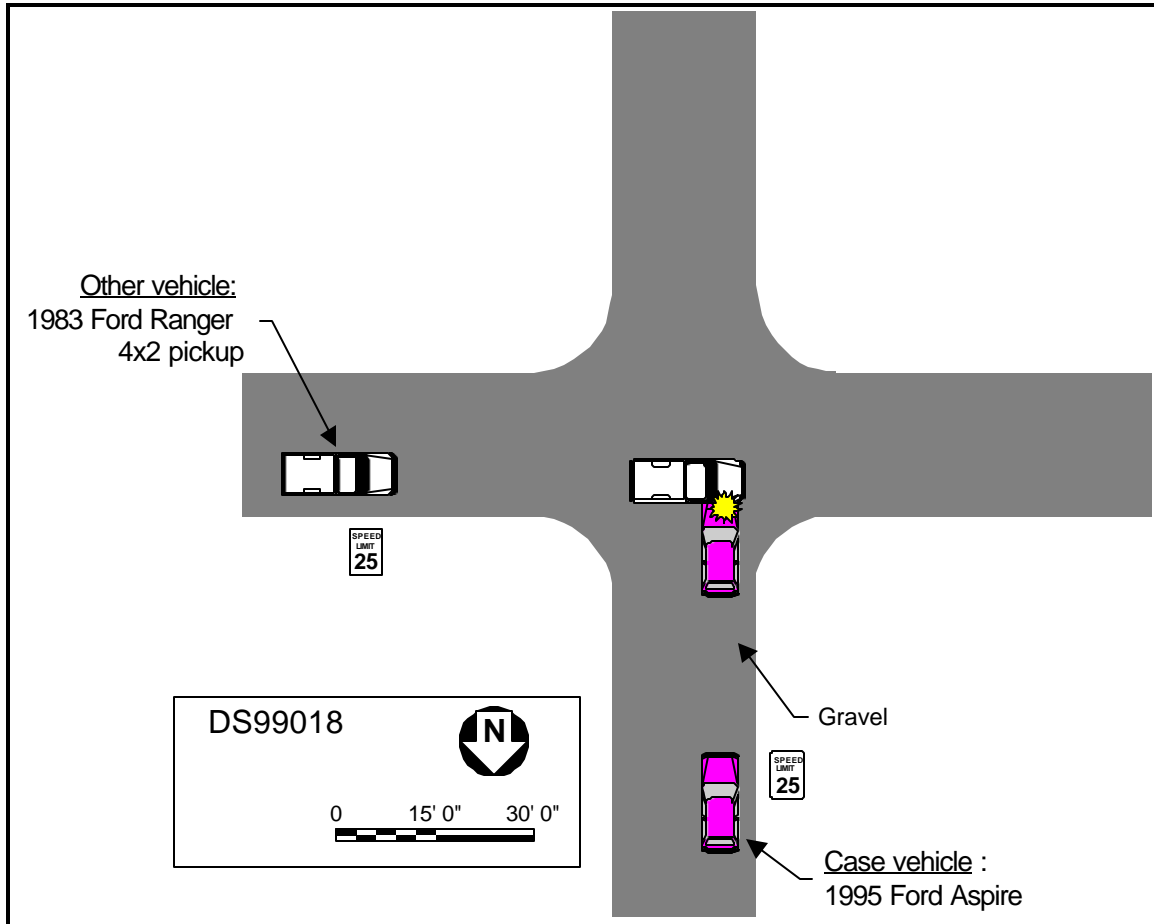


Figure 3. Scene diagram (1 of 2)

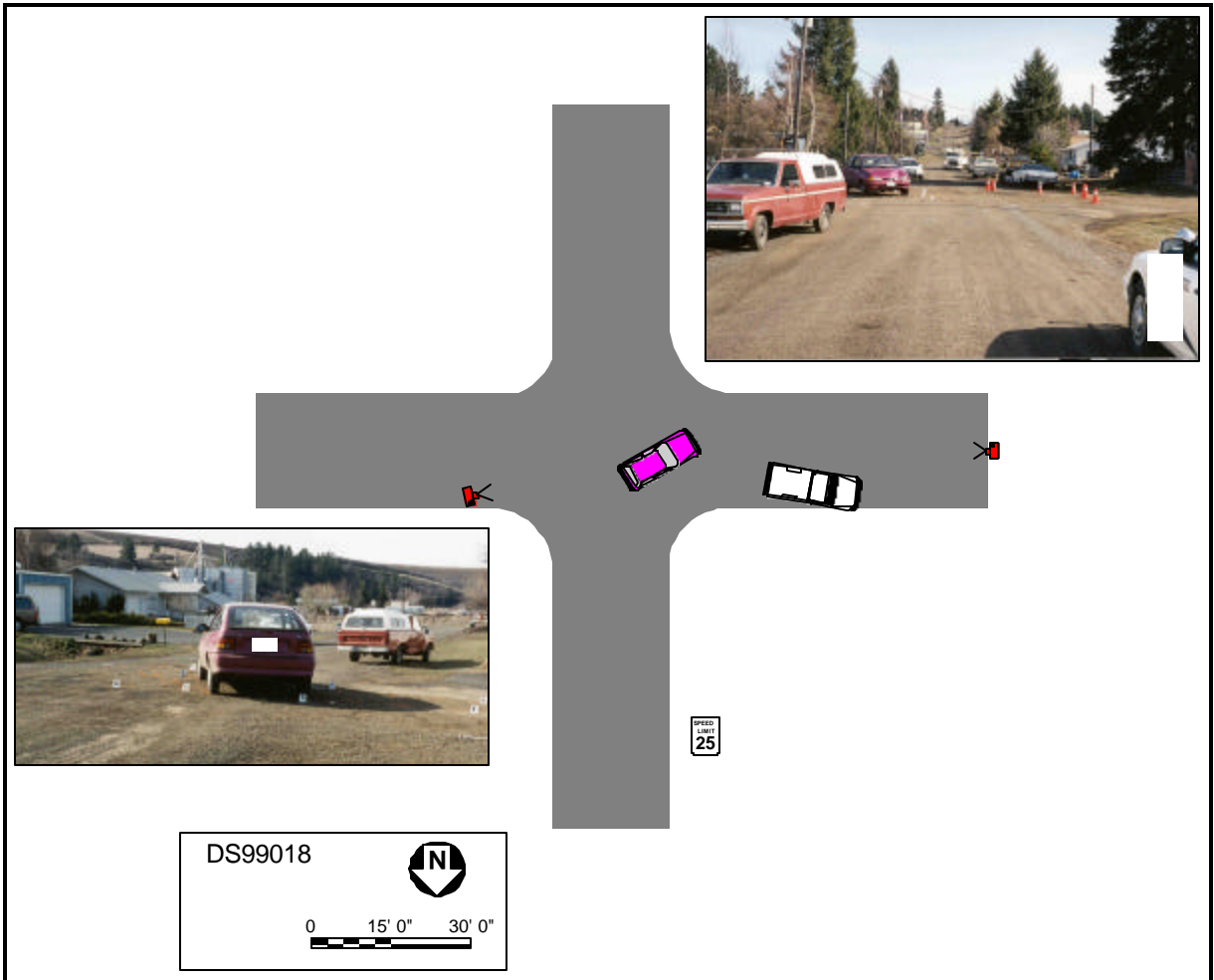


Figure 4. Scene diagram (2 of 2)

DETAILED INFORMATION

Vehicles

Case vehicle

Description:	1995 Ford (Kia Motors, Inc.) Aspire two-door hatchback	
VIN:	KNJLT05H8S6xxxxxx	
Odometer:	98,540 km (61,232 miles)	
Engine:	1.3 L	
Reported Defects:	None noted	
Cargo:	None	
Damage Description:	Moderate rearward crush to entire front bumper, passenger side window disintegrated, “star” impact to windshield.	
CDC:	11FDEW1	
Delta V:	Total	17.2 km/h (10.7 mph)
	Longitudinal	-16.2 km/h (-10.1 mph)
	Latitudinal	5.9 km/h (3.7 mph)
	Energy	11,433 joules (8,438 ft-lbs)



Figure 5. Exterior, case vehicle

Other vehicle

Description: 1983 Ford Ranger 4 x 2 regular cab pickup truck
VIN: 1FTBR10A6DUxxxxx
Odometer: Unknown
Engine: 2.3L 4 CYL
Reported Defects: None noted
Cargo: Camper shell, roof rack.
Damage Description: Moderate lateral damage to right of vehicle.
CDC: 02RYEW3
Delta V:
Total 11.4 km/h (7.1 mph)
Longitudinal -3.9 km/h (-2.4 mph)
Latitudinal -10.7 km/h (-6.6 mph)
Energy 9,693 joules
(7,159 ft-lbs)



Figure 6. Exterior, other vehicle

Occupants

<u>Case vehicle</u>	Occupant 1	Occupant 2
Age/Sex:	40/Male	5/Female
Seated Position:	Front left	Front right
Seat Type:	Bucket with folding back–fabric covered	Bucket with folding back–fabric covered
Height:	Unknown	109 cm (43 in.)
Weight:	Unknown	19.5 kg (43 lbs.)
Occupation:	Unknown	NA
Pre-existing Medical Condition:	None noted	None noted
Alcohol/Drug Involvement:	None	NA
Driving Experience:	Presumed to be > 10 years	NA
Body Posture:	Normal, upright	Normal, upright
Hand Position:	Unknown	Unknown
Foot Position:	Left on floor, right on brake	Unknown
Restraint Usage:	None used	None used
Air bag:	Deployed	Deployed

OccupantsOther vehicle

Age/Sex:	50/Male
Seated Position:	Front left
Seat Type:	Unknown
Height:	Unknown
Weight:	Unknown
Occupation:	Unknown
Pre-existing Medical Condition:	None noted
Alcohol/Drug Involvement:	None
Driving Experience:	Presumed to be > 20 years
Body Posture:	Unknown
Hand Position:	Unknown
Foot Position:	Unknown
Restraint Usage:	Lap only used, per police report

Injuries and Injury Mechanisms

Case vehicle

	<u>INJURY</u>	<u>OIC CODE</u>	<u>ICD-9</u>	<u>SOURCE</u>
Driver:	None reported			
RF Occupant:	Fracture, left supraorbital plane	251202.2,2	801.05	Air bag
	Subluxation c1-c2 cervical spine	650204.2,6	839.01	Side glass frame
	Bilateral subdural hematomas, greatest on right	140652.5,3	852.05	Air bag
	Inferior fronto-temporal contusion hemorrhages, focal	140612.3,2	851.4	Air bag
	Cerebral edema with brain herniation	140668.3,	348.5	Air bag
	Subgaleal hemorrhage, low occipital region near the midline	190402.1,	920.0	Air bag
	Fracture, lower jaw between right mandibular incisor and canine	250604.1,1	802.25	Side glass frame
	Contusion, left cheek ³	290402.1,2	920.0	Air bag
	Contusion, left upper neck			
	Contusion, upper and lower eye lids	390402.1,2	920.0	Air bag
		297402.1,2	921.1	Air bag
	Abrasion, left neck—6 inches in length and up to 3/4 inch in width—possibly related to neck brace	390202.1,2	910.0	Air bag
	Lip contusion	290402.1,8	920	Air bag

Other vehicle

Driver: None reported

3

Begins at brow line and extends downward to left jaw line. Spreads vertically to 5 inches and horizontally to 4-1/2 inches, and centers at approximately the mid-left cheek region at a distance 3-1/2 inches to the left of the midline.

Occupant Kinematics

The front right seat position was occupied by an unrestrained 5-year-old female (109 cm/19.5 kg, 42 in./ 43 lbs.). She was seated in a normal, upright position. This seat position was equipped with a switchable lap and shoulder belt—which was not used—and a mid-mount passenger air bag. The air bag was covered by a curved single flap module cover. At the time of the inspection, the cloth-covered right front seat was in the rearmost track position, but it seems likely that the seat had been moved prior to the inspection.

Prior to entering the intersection, the driver of the case vehicle saw the other vehicle and began braking. The unrestrained front right occupant of Vehicle 1 slid forward toward the instrument panel. Some part of her body (possibly her head) contacted the windshield. She rebounded slightly. The front of the case vehicle (11FDEW1) struck the right A-pillar area of the other vehicle. The case vehicle sustained a longitudinal Δv of -19.7 km/h (-12.2 mph) and a lateral Δv of 7.2 km/h (4.4 mph). Both air bags in the case vehicle deployed at this point.

The front right occupant of the case vehicle sustained a 12.7 x 10.1 cm (5 x 4.5 in.) contusion to the left side of her face, a right lower jaw fracture, a fracture of the left supraorbital plate, a subluxation injury at C1-C2, left and right focal temporal brain contusions, subarachnoid/subdural hemorrhage, and cerebral edema. This occupant survived for three days before expiring.

At impact, the occupant was forward of the seat and her head was nearly level with the instrument panel. As the air bag deployed, the right side of the air bag struck the left side of this occupant's face—causing the facial abrasions. There were two areas of skin transfer to the right side of the passenger side air bag measuring 13 cm (5.1 in.) longitudinally for the upper one and 28 cm (11.0 in.) longitudinally for the lower one. The occupant's head was forced sharply to the right where it struck the side glass and the lower window frame—causing the jaw fracture. The plastic fascia covering the frame was broken and the side glass disintegrated. The investigating officer stated that he found hair from the occupant in the plastic fascia. The movement to the right and the rotation about the frame likely caused the subluxation injury.



Figure 7. Front right seat position, front view



Figure 8. Front right seat, side view



Figure 9. Interior, case vehicle—air bag / side glass frame interaction

The passenger air bag struck the right edge of the center mirror. The mirror rotated about its mounting bracket and struck and fractured the center portion of the windshield before being knocked off. There were no indications of any contact to the module cover.




Figure 10. Side glass frame/door contact



Figure 11. Close-up of skin transfers to right side of passenger air bag