



# INDIANA UNIVERSITY

## TRANSPORTATION RESEARCH CENTER

School of Public and Environmental Affairs

222 West Second Street

Bloomington, Indiana 47403-1501

(812) 855-3908 Fax: (812) 855-3537

## ON-SITE AIR BAG FATALITY INVESTIGATION

CASE NUMBER - IN99-113

LOCATION - Wisconsin

VEHICLE - 1995 CHEVROLET CAVALIER

CRASH DATE - December, 1999

Submitted:

March 27, 2000

Revised Submission:

November 9, 2001



Contract Number: DTNH22-94-D-17058

Prepared for:

U.S. Department of Transportation  
National Highway Traffic Safety Administration  
National Center for Statistics and Analysis  
Washington, D.C. 20590-0003

## **DISCLAIMERS**

This document is disseminated under the sponsorship of the Department of Transportation in the interest of information exchange. The United States Government assumes no responsibility for the contents or use thereof.

The opinions, findings, and conclusions expressed in this publication are those of the authors and not necessarily those of the National Highway Traffic Safety Administration.

The crash investigation process is an inexact science which requires that physical evidence such as skid marks, vehicular damage measurements, and occupant contact points be coupled with the investigator's expert knowledge and experience of vehicle dynamics and occupant kinematics in order to determine the pre-crash, crash, and post-crash movements of involved vehicles and occupants.

Because each crash is a unique sequence of events, generalized conclusions cannot be made concerning the crashworthiness performance of the involved vehicle(s) or their safety systems.

## Technical Report Documentation Page

1. <i>Report No.</i> IN99-113	2. <i>Government Accession No.</i>	3. <i>Recipient's Catalog No.</i>	
4. <i>Title and Subtitle</i> On-Site Air Bag Fatality Investigation Vehicle - 1995 Chevrolet Cavalier Location - Wisconsin		5. <i>Report Date:</i> March 27, 2000; November 9, 2001	
		6. <i>Performing Organization Code</i>	
7. <i>Author(s)</i> Special Crash Investigations Team #2		8. <i>Performing Organization Report No.</i> Task #s 0217 and 0265	
9. <i>Performing Organization Name and Address</i> Transportation Research Center Indiana University 222 West Second Street Bloomington, Indiana 47403-1501		10. <i>Work Unit No. (TRAIS)</i>	
		11. <i>Contract or Grant No.</i> DTNH22-94-D-17058	
12. <i>Sponsoring Agency Name and Address</i> U.S. Department of Transportation (NRD-32) National Highway Traffic Safety Administration National Center for Statistics and Analysis Washington, D.C. 20590-0003		13. <i>Type of Report and Period Covered</i> Technical Report Crash Date: December, 1999	
		14. <i>Sponsoring Agency Code</i>	
15. <i>Supplementary Notes</i> On-site air bag deployment investigation involving a 1995 Chevrolet Cavalier, four-door sedan, with manual three-point safety belts and dual front air bags, and a 1987 Ford Dump truck			
16. <i>Abstract</i> <p>This report covers an on-site investigation of an air bag deployment crash that involved a 1995 Chevrolet Cavalier (case vehicle), and a 1987 Ford LTS 9000 fitted with a dump truck body (other vehicle). This crash is of special interest because the case vehicle's, unrestrained, front unseated passenger (2-year-old male) sustained an unknown traumatic cervical spinal cord injury from the deploying front right passenger air bag module's cover flap, resulting in his death. The case vehicle was traveling north in the northbound lane of a two-lane, undivided, county roadway and was approaching a four-leg intersection. The case vehicle intended to make a left-hand turn and go west. The Ford was traveling west in westbound lane of the same two-lane, undivided, county roadway and was approaching the same four-leg intersection, intending to turn left and travel south. The crash occurred in the four-leg intersection of the roadways. The front right of the case vehicle was impacted and subsequently overridden by the front left of the Ford, causing the case vehicle's driver and front right passenger supplemental restraints (air bags) to deploy. The damage on the case vehicle was primarily above the bumper resembling an underride impact pattern. The underride type damage resulted in the air bag deploying late during the duration of the impact. All three of the case vehicle's occupants were not using their available, active, three-point, lap-and-shoulder, safety belt system. The case vehicle's front unseated passenger was partially standing, leaning forward in the process of climbing over the center console into the front seat. He sustained a traumatic spinal cord injury in conjunction with a high cervical fracture and distraction/dislocation, a laceration under his chin, a large abrasion behind his right ear, and contusions over his lower neck, upper chest, and clavicular areas. The case vehicle's driver (32-year-old female) was seated in an upright posture with her seat track located in its rearmost position, and the vehicle was not equipped with a tilt steering wheel. She sustained a nonanatomic brain injury, a strain to her upper thoracic region, soft tissue injuries to her head and hands, and strained muscles to her left arm and left rib cage. The case vehicle's back left passenger (5-year-old male) was kneeling on the back left seat in an upright posture. He sustained a minor nonanatomic brain injury, a deep laceration to his upper lip (requiring surgery), a laceration inside his mouth; facial contusions; and teeth injuries.</p>			
17. <i>Key Words</i> Air Bag Deployment Motor Vehicle Traffic Crash Injury Severity		18. <i>Distribution Statement</i> General Public	
19. <i>Security Classif. (of this report)</i> Unclassified	20. <i>Security Classif. (of this page)</i> Unclassified	21. <i>No. of Pages</i> 17	22. <i>Price</i> \$9,000

**TABLE OF CONTENTS**

IN99-113

Page No.

BACKGROUND . . . . . 1

SUMMARY . . . . . 1

CRASH CIRCUMSTANCES . . . . . 4

CASE VEHICLE: 1995 CHEVROLET CAVALIER . . . . . 7

    CASE VEHICLE DAMAGE . . . . . 7

    AUTOMATIC RESTRAINT SYSTEM . . . . . 8

    CASE VEHICLE FRONT UNSEATED PASSENGER KINEMATICS . . . . . 11

    CASE VEHICLE FRONT UNSEATED PASSENGER INJURIES . . . . . 11

    CASE VEHICLE DRIVER KINEMATICS . . . . . 12

    CASE VEHICLE DRIVER INJURIES . . . . . 13

    CASE VEHICLE BACK LEFT PASSENGER KINEMATICS . . . . . 14

    CASE VEHICLE BACK LEFT PASSENGER INJURIES . . . . . 15

OTHER VEHICLE: 1987 FORD LTS9000 . . . . . 16

CRASH DIAGRAM . . . . . 17

SELECTED PHOTOGRAPHS . . . . . 18

    Figure 1: Case vehicle’s northward travel path with restricted line-of-sight . . . 4

    Figure 2: Case vehicle’s northward travel path with adequate line-of-sight . . . 4

    Figure 3: Case vehicle’s northward travel path, just prior to impact, showing driver’s intention to turn left and travel west . . . . . 5

    Figure 4: Ford's westward travel path with restricted line-of-sight . . . . . 5

    Figure 5: Ford's westward travel path with adequate line-of-sight . . . . . 5

    Figure 6: Ford's west-southwestward travel path, just prior to impact, while negotiating leftward curving roadway . . . . . 5

    Figure 7: On-scene view looking west-southwest at case vehicle and Ford at final rest positions . . . . . 5

    Figure 8: On-scene close-up of case vehicle under Ford's front bumper . . . . . 6

    Figure 9: Case vehicle’s underride type damage viewed from front . . . . . 6

    Figure 10: Case vehicle’s underride type damage viewed from right of front . . . 6

    Figure 11: Case vehicle’s right instrument panel showing cloth transfers . . . . . 7

TABLE OF CONTENTS (CONTINUED)

IN99-113

SELECTED PHOTOGRAPHS (Continued)		<u>Page No.</u>
Figure 12:	Case vehicle’s front right passenger seating area . . . . .	8
Figure 13:	Close-up of interior surface of case vehicle’s holed right wind- shield . . . . .	8
Figure 14:	Case vehicle’s driver seating area . . . . .	9
Figure 15:	Close-up of cloth transfer on case vehicle driver air bag module’s left cover flap . . . . .	9
Figure 16:	Case vehicle’s driver air bag showing skin and blood on right half . .	9
Figure 17:	Close-up of contact on case vehicle front right air bag module’s cover flap and cloth transfers on top of air bag . . . . .	10
Figure 18:	Case vehicle’s deployed front right air bag . . . . .	10
Figure 19:	Case vehicle’s back left seating area and contacted right “B”-pillar .	15
Figure 20:	Close-up of skin on case vehicle’s right “B”-pillar and right rear window glazing . . . . .	15

This on-site investigation was brought to NHTSA's attention on December 17, 1999 by a private consultant. This crash involved a 1995 Chevrolet Cavalier (case vehicle), and a 1987 Ford Dump truck (other vehicle). The crash occurred in December, 1999, at 3:33 p.m., in Wisconsin and was investigated by the applicable county sheriff. This crash is of special interest because the case vehicle's, unrestrained, front unseated passenger [2-year-old, White (non-Hispanic) male] sustained an unknown traumatic cervical spinal cord injury from the deploying front right passenger air bag module's cover flap, resulting in his death. This contractor inspected the scene and case vehicle on December 21, 1999. This contractor interviewed the driver for the case vehicle on January 3, 2000. This report is based on the Police Crash Report, interviews with the case vehicle's driver and the investigating police officer, scene and vehicle inspections, occupant kinematic principles, occupant medical records, and this contractor's evaluation of the evidence.

## SUMMARY

The case vehicle was traveling north in the northbound lane of a two-lane, undivided, county roadway and was approaching a partially controlled, four-leg intersection. The intersection involved a driveway junction overlaid upon a Tee intersection. The driveway was on the north leg of the intersection and was controlled only by statute. The case vehicle intended to make a left-hand turn and go west. The west leg of the intersection was controlled by a regulatory **STOP** sign. Traffic flow on the south leg was uncontrolled because northbound traffic was expected to either make a 90 degree right-hand turn and continue eastbound or yield to on-coming traffic. The east leg of the intersection was also uncontrolled because traffic was expected to either continue westward or make a 90 degree left-hand turn and continue southward. The Ford was traveling west in westbound lane of the same two-lane, undivided, county roadway and was approaching the same four-leg intersection, intending to turn left and travel south. The case vehicle's driver made no known avoidance maneuvers prior to the crash. The Ford attempted to stop, depositing approximately 13.7 meters (45 feet) of skid marks and rotating approximately 15 degrees counterclockwise prior to the impact. The crash occurred in the four-leg intersection of the roadways; see **CRASH DIAGRAM** below.

The front right of the case vehicle was impacted and subsequently overridden by the front left of the Ford, causing the case vehicle's driver and front right passenger supplemental restraints (air bags) to deploy. The damage on the case vehicle was primarily above the bumper resembling an underride impact pattern. The underride type damage resulted in the air bag deploying late during the duration of the impact. This late deployment occurred due to the prolonged change in time (Delta T) relative to the change in speed (magnitude of Delta V—i.e., ramp versus spike). Both vehicles came to rest near the point of impact in the southwest quadrant of the intersection. The case vehicle rotated approximately 5 degrees counterclockwise and came to rest heading in a northwesterly direction; the Ford came to rest heading in a southwesterly direction.

The case vehicle's front unseated passenger [91 centimeters and 12 kilograms (36 inches, 27 pounds)] was partially standing, leaning forward in the process of climbing over the center console into the front seat, and consequently, he was not using the available, active, three-point,

lap-and-shoulder, safety belt system. In addition, the inspection of the front right passenger seat belt webbing, "D"-ring, and latch plate showed no evidence of loading.

The case vehicle's driver made no known pre-crash avoidance maneuvers. As a result and independent of the nonuse of any available safety belts, the front unseated passenger's pre-impact body position did not change just prior to impact. The case vehicle's impact with the Ford enabled the case vehicle's front unseated passenger to continue forward and rightward toward the case vehicle's 30 degree Direction of Principal Force as the case vehicle decelerated. The front unseated passenger's posture (partially standing) combined with the delay in deployment allowed him to easily move forward slamming his body against the instrument panel with his head reaching atop the front right air bag module's cover flap. Upon deployment, the cover flap contacted the underside of his chin, and the air bag lifted his head upward, into, and almost through the windshield. As the front right air bag continued to expand, the air bag lifted his torso upwards toward the roof and then backwards toward the center console area from which he came. According to the case vehicle's driver, at final rest he was laying in the back center seat position, on his left side, with his upper body twisted to the left.

The front unseated occupant was transported by ambulance to an open area where he was met by a helicopter and airlifted to a hospital. He sustained an unknown traumatic cervical spinal cord injury and was pronounced dead at the hospital approximately one hour post-crash. According to his medical records and interviews with the case vehicle's driver (i.e., mother) and the family's mortician, the injuries sustained by the case vehicle's front unseated passenger included: a spinal cord injury in conjunction with a high cervical fracture and distraction/dislocation, a laceration under his chin, a large abrasion behind his right ear, and contusions over his lower neck, upper chest, and clavicular areas.

The 1995 Chevrolet Cavalier was a front wheel drive, four-door sedan (VIN: 1G1JC5243S7-----). The case vehicle was equipped with four-wheel, anti-lock brakes. The 1987 Ford LTS9000 was a rear wheel drive, incomplete vehicle, fitted with a dump truck body (VIN: 1FDZY90W8HV-----). The case vehicle was towed due to damage. The Ford was driven from the scene. Based on the vehicle inspection, the CDC for the case vehicle was determined to be: **01-FDHW-6 (30)**. Direct damage above the bumper extended rearward 127 centimeters (50.0 inches). The TDC for the Ford is unknown. The WinSMASH reconstruction program could not be executed because the Ford and the damage pattern are both out the scope of the reconstruction program; however, this contractor's visually estimated Delta V is between 16 km.p.h. (10 m.p.h.) and 24 km.p.h. (15 m.p.h.).

The case vehicle's initial contact with the Ford involved the majority of the front, with the crush primarily above the bumper. Direct damage extended from above the right bumper corner (passenger side) to the left, a measured distance of 97 centimeters (38.2 inches). Maximum above bumper crush to the case vehicle's front extended 127 centimeters (50.0 inches) rearward, with direct contact to the windshield. Although the case vehicle's front bumper was not directly contacted, the front right corner sustained induced damage and was pulled rearward 3 centimeters (1.2 inches). The case vehicle's hood and right fender were crushed downward, and the right fender was also crushed inward. The entire length of the case vehicle's right fender sustained

direct damage from contact with the Ford's left front tire and bumper. The direct damage width along the right side was 124 centimeters (48.8 inches), with a maximum crush of 24 centimeters (9.4 inches). The right front tire was directly contacted, resulting in it being deflated and tilted inward at the top.

The case vehicle's driver air bag was located in the steering wheel hub. An inspection of the air bag module's cover flaps and air bag fabric revealed that the cover flaps opened at the designated tear points, and there was no evidence of damage during the deployment to the air bag or the cover flaps. The driver's air bag was designed without any tethers. The driver's air bag had two vent ports, approximately 1 centimeter (0.4 inches) in diameter, located at the 9 and 3 o'clock positions. The deployed driver's air bag was round with diameter 62 centimeters (24.4 inches). There was contact evidence readily apparent (i.e., skin, mucous and blood) on the right half of the driver's air bag, and there appeared to be a cloth transfer on the driver air bag module's left cover flap from contacting the driver. According to the case vehicle's driver, her air bag deployed post-crash, as she was exiting the vehicle. This contractor believes this statement is incorrect, and most likely, the driver only realized that her air bag had deployed when she was exiting the vehicle.

The front right passenger's air bag was located in the top of the instrument panel. An inspection of the front right air bag module's cover flap and air bag fabric revealed that the cover flap opened at the designated tear points; however, it appeared that the deployment was temporarily blocked by contact with the front unseated passenger. The front right air bag was designed with two tethers, but it had no vent ports. The deployed front right air bag was rectangular with a height of approximately 62 centimeters (24.4 inches) and a width of approximately 53 centimeters (20.9 inches). There was no apparent contact evidence on the front surface of the front right passenger's air bag; however, there was contact evidence readily apparent (e.g., an area of red and green cloth transfers and streak of skin transfer) on the top portion of the front right air bag. Furthermore, there appeared to be an oily transfer and tooth gouge on the front right air bag module's cover flap.

In addition, the right "B"-pillar and right rear window glazing show evidence of contact, most likely as a result of being struck by the case vehicle's back left passenger.

Immediately prior to the crash the case vehicle's front unseated passenger was partially standing, leaning forward in the process of climbing over the center console into the front seat; however, the exact positions of his hands/arms and legs/feet are unknown. What is clear is that the child had moved forward enough so that neither of the front seat backs obstructed his forward movement toward the front right air bag module at the time of the crash. The front right seat track was located in its rearmost position, and the seat back was upright.

The case vehicle's driver [32-year-old, White (non-Hispanic) female; 175 centimeters and 125 kilograms (69 inches, 275 pounds)] was seated in an upright posture with her back against the seat back, her left foot on the floor, her right foot on the accelerator, and both hands on the steering wheel. Her seat track was located in its rearmost position with the seat back upright, and the vehicle was not equipped with a tilt steering wheel.



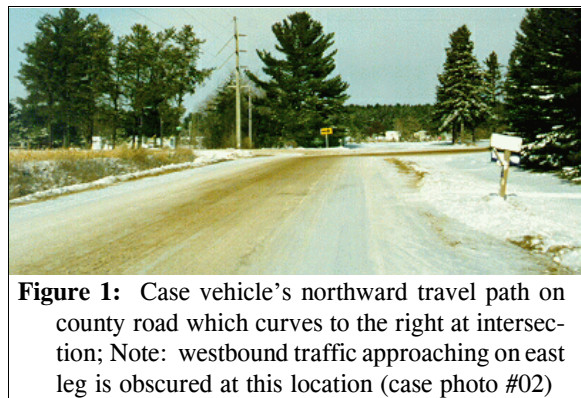
The case vehicle's driver was not using her available, active, three-point, lap-and-shoulder, safety belt system. The driver was transported by ambulance to the hospital. She sustained moderate injuries and was treated and released. According to her interview and her medical records, the injuries sustained by the case vehicle's driver included: a nonanatomic brain injury, a strain to her upper thoracic region, abrasions and contusions to her forehead, several scalp contusions, bilateral periorbital contusions, abrasions to the dorsal surface of both hands, and strained muscles to her left arm and left rib cage.

The case vehicle's back left passenger [5-year-old, White (non-Hispanic) male; 122 centimeters and 22 kilograms (48 inches, 49 pounds)] was kneeling in an upright posture with his back against the seat back and his feet under him. Unfortunately, the exact position of his hands is unknown. His seat track and seat back were not adjustable. At impact this passenger was initially thrown against the backside of the front right seat back prior to sliding across the seat back and impacting the right "B"-pillar and forward portion of the right rear window glazing with his face. Of note was the presence of a secured child safety seat that was unused in the back right position. At final rest the back left passenger was found in the back seat, but his exact position is unknown.

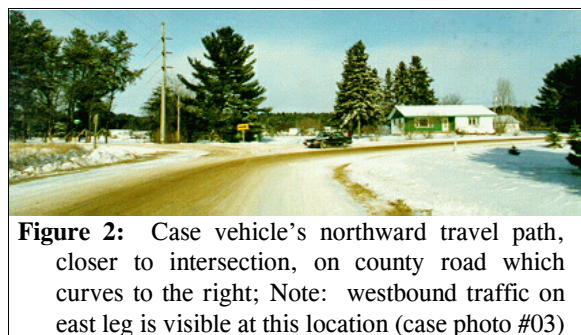
The case vehicle's back left passenger was not using his available, active, three-point, lap-and-shoulder, safety belt system. The passenger was initially transported by ambulance to a local hospital and subsequently transported by ambulance to a trauma facility. He sustained only minor injuries but was taken to surgery and hospitalized for 2 days post-crash. According to the interview with the case vehicle's driver (i.e., mother) and his medical records, the injuries sustained by the back left passenger included: a minor nonanatomic brain injury; a deep laceration to his upper lip (requiring surgery); a laceration inside his mouth; contusions to his nasal area, left eyebrow, and left cheek; an avulsed tooth; and 3 dislocated teeth.

### CRASH CIRCUMSTANCES

The case vehicle was traveling north in the northbound lane of a two-lane, undivided, county roadway and was approaching a partially controlled, four-leg intersection (**Figures 1 and 2**). The intersection involved a driveway junction overlaid upon a Tee intersection. The driveway was on the north leg of the intersection and was controlled only by statute. The case vehicle intended to make a left-hand turn and go west (**Figure 3** below). The west leg of the intersection was controlled by a regulatory **STOP** sign. Traffic flow on the south leg was uncontrolled because northbound traffic was expected to either make a 90 degree right-hand turn and continue



**Figure 1:** Case vehicle's northward travel path on county road which curves to the right at intersection; Note: westbound traffic approaching on east leg is obscured at this location (case photo #02)



**Figure 2:** Case vehicle's northward travel path, closer to intersection, on county road which curves to the right; Note: westbound traffic on east leg is visible at this location (case photo #03)

eastbound or yield to on-coming traffic. The east leg of the intersection was also uncontrolled because traffic was expected to either continue westward or make a 90 degree left-hand turn and continue southward. The Ford was traveling west in westbound lane of the same two-lane, undivided, county roadway (Figures 4 and 5) and was approaching the same four-leg intersection, intending to turn left and travel south (Figure 6). The case vehicle's driver made no known avoidance maneuvers prior to the crash. The Ford attempted to stop, depositing approximately 13.7 meters (45 feet) of skid marks and rotating approximately 15 degrees counterclockwise prior to the impact (Figure 7). The crash occurred in the four-leg intersection of the roadways; see **CRASH DIAGRAM** below.



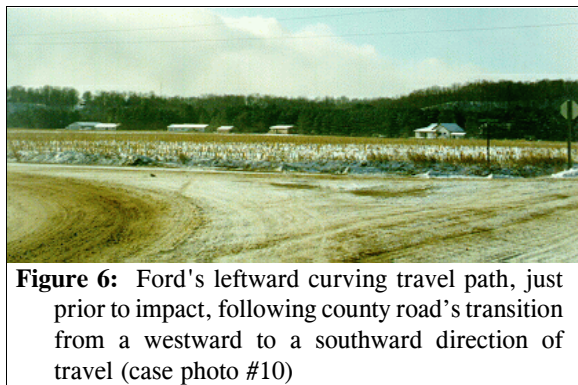
**Figure 3:** Case vehicle's northward approach to four-leg intersection just prior to impact; Note: case vehicle intended to turn left and travel west on an intersecting county roadway (case photo #05)



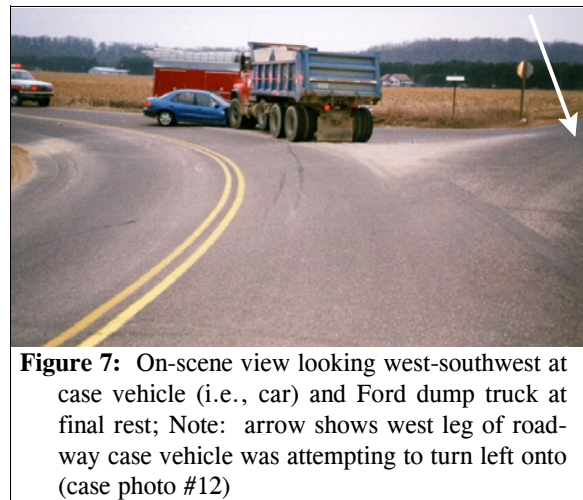
**Figure 4:** Ford's westward travel path on county road that curves to the south at intersection; Note: northbound traffic is not visible at this location (case photo #07)



**Figure 5:** Ford's westward travel path, closer to intersection, on county road that curves to the south at intersection; Note: northbound traffic is visible at this location (case photo #08)



**Figure 6:** Ford's leftward curving travel path, just prior to impact, following county road's transition from a westward to a southward direction of travel (case photo #10)



**Figure 7:** On-scene view looking west-southwest at case vehicle (i.e., car) and Ford dump truck at final rest; Note: arrow shows west leg of roadway case vehicle was attempting to turn left onto (case photo #12)

The county roadway was straight, in the pre-crash direction of travel for both vehicles, just prior to their entering the intersection. The case vehicle's approach path had a 2% grade, negative to the north; vehicle 2's approach path had a 3% grade, negative to the west. The pavement was bituminous for both vehicles, and the width of the travel lanes for both vehicles is unknown. The shoulders on the road segments approaching



the intersection from both the south and east were not improved. Pavement markings consisted of double solid yellow centerlines on the road segments approaching the intersection from both the south and east, and these pavement markings continued through the county roadway's curving intersection (**Figure 7** above). In addition, solid white edge lines were present. At the area of impact there was an abundance of loose gravel making the estimated coefficient of friction 0.60%. A **LARGE ARROW** warning sign (Manual on Uniform Traffic Control Devices, W1-6) was located on the north side of the intersection providing a warning for northbound traffic (**Figure 3** above). The posted speed limit for both vehicles was 72 km.p.h. (45 m.p.h.). At the time of the crash the light condition was dusk, the atmospheric condition was cloudy, and the road pavement was dry. Traffic density was moderate, and the site of the crash was rural agricultural. In addition, there was a driveway to a residence within the intersection of the crash site.



**Figure 8:** On-scene close-up of case vehicle under Ford's front bumper; Note: deployed driver and front right passenger air bags (case photo #15)



**Figure 9:** Case vehicle's underride type damage to front and right side from impact with Ford; Note: yellow tape highlights width of hood that was overridden (case photo #17)

The front right of the case vehicle was impacted and subsequently overridden by the front left of the Ford (**Figure 8**), causing the case vehicle's driver and front right passenger supplemental restraints (air bags) to deploy. The damage on the case vehicle was primarily above the bumper resembling an underride impact pattern (**Figures 9** and **10**). The underride type damage resulted in the air bag deploying late during the duration of the impact. This late deployment occurred due to the prolonged change in time (Delta T) relative to the change in speed (magnitude of Delta V--i.e., ramp versus spike). Both vehicles came to rest near the point of impact in the southwest quadrant of the intersection. The case vehicle rotated approximately 5 degrees counterclockwise and came to rest heading in a northwesterly direction; the Ford came to rest heading in a southwesterly direction.



**Figure 10:** Case vehicle's frontal damage; Note: override type deformation, damaged right front wheel, and starred windshield (case photo #33)

The 1995 Chevrolet Cavalier was a front wheel drive, five-passenger, four-door sedan (VIN: 1G1JC5243S7-----) equipped with a 2.2L, MPFI OHV, L-4 engine, power assisted rack-and-pinion steering, and a three-speed automatic transmission. Braking was achieved by a power-assisted, four wheel, anti-lock system. The case vehicle's wheelbase was 264 centimeters (104.1 inches), and the odometer reading at inspection was 155,836 kilometers (96,832 miles).

The case vehicle's front seating area was equipped with adjustable bucket seats, containing adjustable head restraints. The rear seat was a non-adjustable bench seat, without head restraints. The case vehicle had three-point, lap-and-shoulder, safety belt systems in both the front and rear outboard seating positions and a manual, two-point, lap belt in the back center seating position. The vehicle was equipped with rigid plastic knee bolsters for both the driver and front right passenger. The front belt systems were equipped with manually operated height adjusters for the "D"-rings. Automatic restraint was provided by a Supplemental Restraint System (SRS) that consisted of a frontal air bags for the driver and front right seating positions.

#### CASE VEHICLE DAMAGE

The case vehicle's initial contact with the Ford involved the majority of the front, with the crush primarily above the bumper (**Figure 9** above). Direct damage extended from above the right bumper corner (passenger side) to the left, a measured distance of 97 centimeters (38.2 inches). Maximum above bumper crush to the case vehicle's front extended 127 centimeters (50.0 inches) rearward. In addition, the base of the right windshield was also severely cracked from direct contact with the Ford's front bumper. Although the case vehicle's front bumper was not directly contacted, the front right corner sustained induced damage and was pulled rearward 3 centimeters (1.2 inches). The case vehicle's hood and right fender were crushed downward, and the right fender was also crushed inward. The entire length of the case vehicle's right fender sustained direct damage from contact with the Ford's left front tire and bumper. The direct damage width along the right side was 124 centimeters (48.8 inches), with a maximum crush of 24 centimeters (9.4 inches). The right front tire was directly contacted, resulting in it being deflated and tilted inward at the top (**Figure 10** above). The case vehicle was towed due to damage.

An examination of the case vehicle's interior revealed a scuff mark to the driver's knee bolster, from contact by the driver, and the presence of cloth transfers to the right knee bolster/instrument panel (**Figure 11**) from impact by the torso of the case vehicle's front unseated passenger. There was a spider web crack to the right windshield from contact by the front unseated passenger's head (**Figures 12** and **13** below). The roof near the front header and rearview mirror was contacted by the front unseated passenger's foot. The rearview mirror was also askew, either from contact with the front unseated passenger's leg, or



**Figure 11:** Apparent occupant cloth transfers to case vehicle's right instrument panel from front unseated passenger (case photo #47)



more likely by the fabric of the deploying front right air bag. In addition, the energy absorbing steering column (i.e., shear capsules) showed evidence of compression, which was measured at 1 centimeters (0.4 inches). The bottom half of the steering wheel rim was bent toward the instrument panel approximately 2 centimeters (0.8 inches). Finally, the right “B”-pillar was scuffed and a piece of skin, from contact by the back left passenger’s upper lip, was still attached to it. The right rear window glazing was misaligned and also had a oily smear near the “B”-pillar contact.



**Figure 13:** Close-up of interior surface of case vehicle’s holed right windshield; Note: windshield contacted by head of front unseated passenger (case photo #50)



**Figure 12:** Case vehicle’s front right passenger seating area showing occupant contacts to roof, windshield, top of air bag and air bag module’s cover flap (case photo #48)

Based on the vehicle inspection, the CDC for the case vehicle was determined to be: **01-FDHW-6 (30)**. The WinSMASH reconstruction program could not be executed because the Ford and the damage pattern (i.e., underride) are both out the scope of the reconstruction program; however, this contractor’s visually estimated Delta V is between 16 km.p.h. (10 m.p.h.) and 24 km.p.h. (15 m.p.h.).


#### **AUTOMATIC RESTRAINT SYSTEM**

As previously mentioned, the case vehicle was equipped with a SRS that consisted of frontal air bags at both the driver and front right passenger seating positions. The SRS deployed as a result of the case vehicle’s frontal impact with the front left of the Ford. The case vehicle’s driver air bag was located in the steering wheel hub (**Figure 14** below). The module cover consisted of symmetrical “I”-configuration cover flaps made of thick vinyl with an overall dimension of 22 centimeters (8.7 inches) at the upper and lower horizontal seams [i.e., each flap was 11 centimeters (4.33 inches) wide] and 10 centimeters (3.9 inches) vertically. An inspection of the air bag module’s cover flaps and air bag fabric revealed that the cover flaps opened at the designated tear points, and there was no evidence of damage during the deployment to the air bag or the cover flaps; however, there appeared to be a cloth transfer on the driver air bag module’s


left cover flap from contacting the driver (**Figure 15**). The driver's air bag was designed without any tethers. The driver's air bag had two vent ports, approximately 1 centimeter (0.4 inches) in diameter, located at the 9 and 3 o'clock positions. The deployed driver's air bag was round with diameter 62 centimeters (24.4 inches). According to the case vehicle's driver, her air bag deployed post-crash, as she was exiting the vehicle. This contractor believes this statement is incorrect, and most likely, the driver only realized that her air bag had deployed when she was exiting the vehicle.



**Figure 14:** Case vehicle's driver seating area showing deployed driver air bag and cloth transfer on air bag module's left cover flap; Note: steering wheel has been rotated approximately 100 degrees clockwise in this photo (case photo #38)



**Figure 15:** Close-up of red cloth transfer on case vehicle driver air bag module's left cover flap (case photo #40)



**Figure 16:** Case vehicle's driver air bag showing skin and mucous (within circular area) and blood (arrows) on right half of air bag; Note: steering wheel rotated approximately 100 degrees clockwise (case photo #42)

An inspection of the case vehicle's driver air bag revealed two small areas of contact blood to the right half of the air bag's front surface (**Figure 16**). All the blood, presumably, came from one or both of the driver's abraded hands (i.e., dorsal surfaces) because the front unseated passenger was thrown, post-impact, rearward onto the case vehicle back seat; see kinematic discussion below. In addition, there was an 8 x 7 centimeter (3.1 x 2.8 inch) area of skin and mucous to the upper half of the air bag towards the top. There were black striations to the back portion of the driver's air bag on the right side as a result of the driver temporarily blocking the air bag's deployment path.



The front right passenger air bag was located in the top of the front right dash. There was a single, essentially rectangular, modular cover flap. The cover flap was made of a thick vinyl over a thick cardboard type frame. The flap's dimensions were 30.5 centimeters (12.0 inches) at the upper horizontal seam and 19 centimeters (7.5 inches) along both side seams. The profile of the case vehicle's instrument panel/dash resulted in a 12 centimeter (4.7 inch) setback of the leading edge of the cover flap relative to the protruding right instrument panel. An inspection of the front right air bag module's cover flaps and air bag fabric revealed that the cover flaps opened at the designated tear points along the front and outer edges; however, it appeared that the deployment was temporarily blocked by contact with the front unseated passenger. Specifically, the inspection of the cover flap revealed a 14 x 10 centimeter (5.5 x 3.9 inch) area of deformation (i.e., an oily skin transfer and an apparent tooth gouge) from the front unseated passenger's chin and mouth (**Figure 17**). The area of deformation on the cover flap was located along the front/leading edge of the flap, 8 centimeters (3.2 inches) inwards from both sides, and extended forward (i.e., toward the windshield) 10 centimeters (3.9 inches) from the leading edge of the cover flap.



**Figure 17:** Close-up of case vehicle front right air bag module's contacted cover flap (yellow dot) and faint red and green cloth transfer to top of air bag (case photo #53)



**Figure 18:** Case vehicle's front right passenger air bag showing no apparent evidence of contact from front unseated passenger (case photo #57)

The front right air bag was designed with two internal tethers, each 7 centimeters (2.8 inches) in width. Both tethers were sewn to the interior face of the air bag at points that were approximately 20 centimeters (7.9 inches) below the top edge and 12 centimeters (4.7 inches) inwards from each side. The front right air bag had no vent ports. The deployed front right air bag was rectangular with a height of approximately 62 centimeters (24.4 inches) and a width of approximately 53 centimeters (20.9 inches). Examination of the front right passenger air bag revealed a 15 centimeter (5.9 inches) long green and red cloth transfer to the top portion of the air bag towards the left side. The examination also revealed a 9 centimeter (3.5 inches) long skin transfer to the right of the cloth transfer. Both the skin and cloth transfers started just below the cover flap (**Figure 17**). The front

surface of the deployed air bag showed no evidence of occupant contact by the front unseated passenger (**Figure 18** above).

#### **CASE VEHICLE FRONT UNSEATED PASSENGER KINEMATICS**

Immediately prior to the crash the case vehicle's front unseated passenger [2-year-old, White (non-Hispanic) male; 91 centimeters and 12 kilograms (36 inches, 27 pounds)] was partially standing, leaning forward in the process of climbing over the center console into the front seat. As a result, the exact positions of his hands/arms and legs/feet are unknown. What is clear is that the child had moved forward enough so that neither of the front seat backs obstructed his forward movement toward the front right air bag module at the time of the crash. The front right seat track was located in its rearmost position, and the seat back was upright.

Consequently, the case vehicle's front unseated passenger was not using the available, active, three-point, lap-and-shoulder, safety belt system. As expected, the inspection of the front right passenger seat belt webbing, "D"-ring, and latch plate showed no evidence of loading.

The case vehicle's driver made no known pre-crash avoidance maneuvers. As a result and independent of the nonuse of any available safety belts, the front unseated passenger's pre-impact body position did not change just prior to impact. The case vehicle's impact with the Ford enabled the case vehicle's front unseated passenger to continue forward and rightward toward the case vehicle's 30 degree Direction of Principal Force as the case vehicle decelerated. The front unseated passenger's posture (partially standing) combined with the delay in deployment allowed him to easily move forward slamming his body against the instrument panel (**Figure 11** above) with his head reaching atop the front right air bag module's cover flap. Upon deployment, the cover flap contacted the underside of his chin (**Figure 17** above), and the air bag lifted his head upward, into, and almost through the windshield (**Figure 13** above). As the front right air bag continued to expand, the air bag lifted his torso upwards toward the roof and then backwards toward the center console area from which he came. According to the case vehicle's driver, at final rest he was laying in the back center seat position, on his left side, with his upper body twisted to the left.

#### **CASE VEHICLE FRONT UNSEATED PASSENGER INJURIES**

The front unseated occupant was transported by ambulance to an open area where he was met by a helicopter and airlifted to a hospital. He sustained an unknown traumatic cervical spinal cord injury and was pronounced dead at the hospital approximately one hour post-crash. According to his medical records and interviews with the case vehicle's driver (i.e., mother) and the family's mortician, the injuries sustained by the case vehicle's front unseated passenger included: a spinal cord injury in conjunction with a high cervical fracture and distraction/dislocation, a laceration under his chin, a large abrasion behind his right ear, and contusions over his lower neck, upper chest, and clavicular areas.



Injury Number	Injury Description (including Aspect)	NASS Injury Code & AIS 90	Injury Source (Mechanism)	Source Confidence	Source of Injury Data
1	Injury, traumatic, to cervical spinal cord <sup>1</sup>	615999.7 unknown	Front right module's cover flap	Probable	Emergency room records
2	Fracture, significant, upper cervical spine with wide distraction <sup>2</sup> / separation between C <sub>2</sub> and C <sub>3</sub>	650216.2 moderate	Front right module's cover flap	Probable	Emergency room records
3	Laceration, 3.8 cm (1½ in) long, under chin	290602.1 minor	Front right module's cover flap	Probable	Other: mortician
4	Abrasion {scrape}, 7.6 x 5.1 cm (3 x 2 in), behind right ear	190202.1 minor	Windshield	Probable	Other: mortician
5	Contusion lower neck, not further specified [Aspect = Unknown]	390402.1 minor	Air bag, front right passenger's	Probable	Other: mortician
6	Contusion upper chest, not further specified [Aspect = Unknown]	490402.1 minor	Air bag, front right passenger's	Probable	Other: mortician
7	Contusion, deep, over clavicle, not further specified [Aspect = Unknown]	790402.1 minor	Air bag, front right passenger's	Probable	Other: mortician
8	Injury, thoracic cavity {internal chest}, not further specified	442299.7 unknown	Unknown source	Unknown	Interviewee (driver)

## CASE VEHICLE DRIVER KINEMATICS

The case vehicle's driver [32-year-old, White (non-Hispanic) female; 175 centimeters and 125 kilograms (69 inches, 275 pounds)] was seated in an upright posture with her back against the seat back, her left foot on the floor, her right foot on the accelerator, and both hands on the steering wheel. Her seat track was located in its rearmost position with the seat back upright, and the vehicle was not equipped with a tilt steering wheel.

<sup>1</sup> The involvement of the spinal cord is based on two factors. First, the ICD-9-CM code of "806.0" was cited on the Emergency Room Report, and second, two emergency room physicians who examined this patient both indicated that there was a significant spinal fracture that was incompatible with life (i.e., obviously referring to an injury to the cord). The only available medical records are Emergency Room-related reports in which this occupant was in cardiorespiratory arrest on arrival and declared "dead" within thirty (30) minutes of arrival because of the patient's lack of response to treatment. Although the doctors never specifically mention the patient's spinal cord, it was obvious to this contractor that the doctors' diagnosis was based on their experience and their review of the cervical radiographs (i.e., there was no subsequent invasive examination performed, and the radiographic records were referenced but not provided).

<sup>2</sup> The following term is defined in DORLAND'S ILLUSTRATED MEDICAL DICTIONARY as follows:  
**distraction (dis-trak-shen)**: a form of dislocation in which the joint surfaces have been separated without rupture of their binding ligaments and without displacement.

The case vehicle's driver was not using her available, active, three-point, lap-and-shoulder, safety belt system. As expected, the inspection of the driver's seat belt webbing, "D"-ring, and latch plate showed no evidence of loading, and she had no injuries consistent with restraint usage.

The case vehicle's driver made no known pre-crash avoidance maneuvers. As a result and independent of the nonuse of any available safety belts, the driver's pre-impact body position did not change just prior to impact. The case vehicle's impact with the Ford enabled the case vehicle's driver to continue forward and rightward toward the case vehicle's 30 degree Direction of Principal Force as the case vehicle decelerated. The delay in deployment allowed her to easily move forward contacting the knee bolster and simultaneously placing her torso in a position very close to the steering wheel-mounted, driver air bag module. Upon deployment, the cover flaps may have contacted the clothing covering the driver's chest causing the cloth transfer on the cover flaps (**Figures 14 and 15** above); however, given that the case vehicle's driver sustained no medically reported chest or abdominal injuries, it is unlikely that the driver air bag module's cover flaps made any significant contact with the driver's torso. The case vehicle's driver was most likely bent forward, with her head leading her torso, just prior to deployment. As a result, the driver's forehead most likely contacted the deploying air bag just below the 12 o'clock position depositing the noted skin and mucous and resulting in the injuries to her forehead. As the air bag continued to expand, the driver's head was knocked backwards and possibly upwards causing her nonanatomic brain injury and her upper thoracic strain. The driver's girth helped protect her as the air bag continued to expand, knocking her backwards and to the right into her seat back. At final rest she remained in her seat but out of her initial pre-crash position.

**CASE VEHICLE DRIVER INJURIES**

The driver was transported by ambulance to the hospital. She sustained moderate injuries and was treated and released. According to her interview and her medical records, the injuries sustained by the case vehicle's driver included: a nonanatomic brain injury, a strain to her upper thoracic region, abrasions and contusions to her forehead, several scalp contusions, bilateral periorbital contusions, abrasions to the dorsal surface of both hands, and strained muscles to her left arm and left rib cage.

Injury Number	Injury Description (including Aspect)	NASS Injury Code & AIS 90	Injury Source (Mechanism)	Source Confidence	Source of Injury Data
1	Nonanatomic brain injury with an altered level of consciousness {obtunded} and vomiting at scene, GCS = 14 at scene, but no loss of consciousness	160606.2 moderate	Air bag, driver's	Probable	Emergency room records
2	Strain upper thoracic spine with tenderness over T <sub>1</sub> -T <sub>2</sub>	640478.1 minor	Air bag, driver's	Probable	Emergency room records
3	Abrasion forehead, not further specified	290202.1 minor	Air bag, driver's	Certain	Emergency room records

Injury Number	Injury Description (including Aspect)	NASS Injury Code & AIS 90	Injury Source (Mechanism)	Source Confidence	Source of Injury Data
4	Contusion left forehead	290402.1 minor	Air bag, driver's	Certain	Emergency room records
5	Abrasions both hands, dorsal <sup>3</sup> surfaces [Aspect = bilateral]	790202.1 minor	Air bag, driver's	Possible	Emergency room records
6 7	Contusions <sup>4</sup> , multiple, lower limbs, not further specified	890402.1 minor 890402.1 minor	Knee bolster {left knee} Center instrument panel and below {right knee}	Probable	Emergency room records
8	Contusions {bumps} to top of head, not further specified	190402.1 minor	Roof	Possible	Interviewee (same person)
9 10	Contusions {black and blue} bilateral eyes	297402.1 297402.1 minor	Air bag, driver's	Probable	Interviewee (same person)
11	Strain left thoracic cavity chest wall	442214.1 minor	Steering wheel rim <sup>5</sup>	Possible	Interviewee (same person)
12	Strain left arm muscle, not further specified	740402.1 minor	Steering wheel rim <sup>5</sup>	Possible	Interviewee (same person)

### CASE VEHICLE BACK LEFT PASSENGER KINEMATICS

The case vehicle's back left passenger [5-year-old, White (non-Hispanic) male; 122 centimeters and 22 kilograms (48 inches, 49 pounds)] was kneeling in an upright posture with his back against the seat back and his feet under him. Unfortunately, the exact position of his hands is unknown. His seat track and seat back were not adjustable.

The case vehicle's back left passenger was not using his available, active, three-point, lap-and-shoulder, safety belt system. As expected, the inspection of the back left passenger's seat belt

<sup>3</sup> The following terms are defined in DORLAND'S ILLUSTRATED MEDICAL DICTIONARY as follows:

*dorsal (dor'sal)*: 1. pertaining to the back or to any dorsum. 2. denoting a position more toward the back surface than some other object or reference; same as posterior in human anatomy....

*dorsum (dor'sem)*: 1. the back. 2. the aspect of an anatomical part or structure corresponding in position to the back; posterior, in the human.

*d. of hand*: d. manus.

*d. ma'nus*: the back of the hand; the surface opposite the palm.

<sup>4</sup> Based on the driver's interview, these contusions were most likely to her knees.

<sup>5</sup> In this contractor's opinion, the case vehicle's driver was most likely hanging onto the steering wheel rim with her left hand (at least) when the crash occurred. As the driver moved rapidly toward the 30 degree Direction of Principal Force, her left hand remained attached to the rim causing a "yanking" action on her left rib cage and arm, thus straining the applicable muscles. This mechanism of injury is consistent with a person who rotates over their safety restraint, straining their back muscles.

webbing, "D"-ring, and latch plate showed no evidence of loading, and he had no injuries consistent with restraint usage.

The case vehicle's driver made no known pre-crash avoidance maneuvers. As a result and independent of the nonuse of any available safety belts, the back left passenger's pre-impact body position did not change just prior to impact. The case vehicle's impact with the Ford enabled the back left passenger to continue forward and rightward toward the case vehicle's 30 degree Direction of Principal Force as the case vehicle decelerated. At impact this passenger was initially thrown against the backside of the front right seat back prior to sliding across the seat back and impacting the right "B"-pillar and forward portion of the right rear window glazing with his face (Figures 19 and 20).


Of note was the presence of a secured child safety seat that was unused in the back right position. According to the case vehicle's driver, at final rest he was found back near his original seat, leaning against the door. This statement is problematic because it requires the post-impact trajectories of the case vehicle's two, unrestrained children to crisscross one another as they rebounded backward toward their respective final rest positions. In this contractor's opinion, the front unseated passenger and the back left passenger both came to final rest in the back seat, but their exact positions are unknown.

#### CASE VEHICLE BACK LEFT PASSENGER INJURIES

The passenger was initially transported by ambulance to a local hospital and subsequently transported by ambulance to a trauma facility. He sustained only minor injuries but was taken to surgery and hospitalized for 2 days post-crash. According to the interview with the case vehicle's driver (i.e., mother) and his medical records, the injuries sustained by the back left passenger included: a minor nonanatomic brain injury; a deep laceration to his upper lip (requiring surgery); a laceration inside his mouth; contusions to his nasal area, left eyebrow, and left cheek; an avulsed tooth, and 3 dislocated teeth.



**Figure 19:** Case vehicle's back left seating area and contacted "B"-pillar (i.e., yellow dots); Note: unused, secured, child safety seat in back right position (case photo #58)



**Figure 20:** Close-up of skin on case vehicle's right "B"-pillar and rear window glazing from contact by back left passenger's face (case photo #60)

Injury Number	Injury Description (including Aspect)	NASS Injury Code & AIS 90	Injury Source (Mechanism)	Source Confidence	Source of Injury Data
1	Nonanatomic brain injury; awake, GCS=15, no loss of consciousness, but vomiting (emesis x 2)	160402.1 minor	Right "B"-pillar	Probable	Hospitalization records
2	Contusion {bruise} with edema over nasion and glabellar area <sup>6</sup>	290402.1 minor	Right "B"-pillar	Probable	Hospitalization records
3	Laceration, complex, 4 cm (1.6 in), through and through, left upper lip, extending down to maxilla and toward left nasal alae <sup>7</sup>	290602.1 minor	Right "B"-pillar	Probable	Hospitalization records
4	Laceration upper gingiva with contamination	243204.1 minor	Right "B"-pillar	Probable	Hospitalization records
5	Avulsion left upper medial incisor	251406.1 minor	Right "B"-pillar	Probable	Hospitalization records
6	Loosened three anterior incisors	251402.1 minor	Right "B"-pillar	Probable	Hospitalization records
7	Contusion {bruise} with swelling left eyebrow	290402.1 minor	Right "B"-pillar	Probable	Interviewee (driver)
8	Contusion {bruise} with swelling left cheek	290402.1 minor	Right "B"-pillar	Probable	Interviewee (driver)

## OTHER VEHICLE

The 1987 Ford LTS9000 was a rear wheel drive, chassis cab, incomplete vehicle fitted with a dump truck body (VIN: 1FDZY90W8HV-----). The Ford was equipped with a 14.0L (855 C.I.D.), I-6 Cummins diesel engine, and a nine-speed manual transmission was standard. Anti-lock brakes were not an option for this model. The case vehicle's wheelbase and odometer reading at the time of the crash are unknown. The TDC for the Ford is unknown. The WinSMASH reconstruction program could not be executed because the Ford and the damage pattern (i.e., override) are both out the scope of the reconstruction program. The Ford was driven from the scene.

<sup>6</sup> The following terms are defined in DORLAND'S ILLUSTRATED MEDICAL DICTIONARY as follows:

**glabella** (*gle-bel'e*): 1. the smooth area on the frontal bone between the superciliary arches. 2. the most prominent point in the median plane between the eyebrows; used as an anthropometric landmark.

**glabellar** (*gle-bel'er*): pertaining to the glabella.

**nasion** (*na-ke-on*): a cephalometric landmark located where the intranasal and nasofrontal sutures meet; it corresponds roughly to the depression at the root of the nose just inferior to the level of the eyebrows.

<sup>7</sup> The following terms are defined in DORLAND'S ILLUSTRATED MEDICAL DICTIONARY as follows:

**ala** (*a'le*): a general term for a winglike structure or process; called also *wing*.

**a. na'si** : wing of nose: the flaring cartilaginous expansion forming the outer side of each naris.

**alae** (*a'le*): plural of *ala*.

