

CRASH DATA RESEARCH CENTER

Calspan Corporation
Buffalo, NY 14225

CALSPAN ON-SITE AMBULANCE CRASH INVESTIGATION

SCI CASE NO: CA09076

VEHICLE: 1998 FORD E350 TYPE III AMBULANCE

LOCATION: TENNESSEE

CRASH DATE: OCTOBER, 2009

Contract No. DTNH22-07-C-00043

Prepared for:

U.S. Department of Transportation
National Highway Traffic Safety Administration
Washington, D.C. 20590

DISCLAIMER

This document is disseminated under the sponsorship of the Department of Transportation in the interest of information exchange. The United States Government assumes no responsibility for the contents or use thereof.

The opinions, findings, and conclusions expressed in this publication are those of the authors and not necessarily those of the National Highway Traffic Safety Administration.

The crash investigation process is an inexact science which requires that physical evidence such as skid marks, vehicular damage measurements, and occupant contact points are coupled with the investigator's expert knowledge and experience of vehicle dynamics and occupant kinematics in order to determine the pre-crash, crash, and post-crash movements of involved vehicles and occupants.

Because each crash is a unique sequence of events, generalized conclusions cannot be made concerning the crashworthiness performance of the involved vehicle(s) or their safety systems.

TECHNICAL REPORT STANDARD TITLE PAGE

<p>1. Report No. CA09076</p>	<p>2. Government Accession No.</p>	<p>3. Recipient's Catalog No.</p>	
<p>4. Title and Subtitle Calspan On-Site Ambulance Crash Investigation Vehicle: 1998 Ford E350 Type III Ambulance Location: State of Tennessee</p>		<p>5. Report Date: February 2010</p>	
		<p>6. Performing Organization Code</p>	
<p>7. Author(s) Crash Data Research Center</p>		<p>8. Performing Organization Report No.</p>	
<p>9. Performing Organization Name and Address Crash Data Research Center Calspan Corporation P.O. Box 400 Buffalo, New York 14225</p>		<p>10. Work Unit No. C00500.0000.0119</p>	
		<p>11. Contract or Grant No. DTNH22-07-C-00043</p>	
<p>12. Sponsoring Agency Name and Address U.S. Department of Transportation National Highway Traffic Safety Administration Washington, D.C. 20590</p>		<p>13. Type of Report and Period Covered Technical Report Crash Date: CA09076</p>	
		<p>14. Sponsoring Agency Code</p>	
<p>15. Supplementary Note This on-site investigation focused on the front-to-rear crash of a 1998 Ford E350 Type III ambulance and a stopped 2006 GMC K3500 work truck.</p>			
<p>16. Abstract This on-site investigation focused on the front-to-rear crash of a 1998 Ford E350 Type III ambulance and a stopped 2006 GMC K3500 work truck. The ambulance was conducting a non-emergency transport of a 78-year-old female patient from a dialysis treatment back to her assisted-living-center home at the time of the crash. The restrained 36-year-old male driver and the patient were fatally injured. The unrestrained 51-year-old male paramedic seated on the right bench seat within the patient compartment sustained severe injuries. The crash occurred during the daylight hours in clear weather conditions. The ambulance had traveled from on an on-ramp and had just merged onto a northbound interstate. It was in the outboard lane. The work truck was stopped on the right shoulder on the east side of the interstate. The ambulance drifted onto the shoulder, impacted and underrode the back of the truck. The ambulance sustained severe frontal damage as a result of the impact. The frontal air bags in the ambulance deployed. The ambulance driver sustained fatal blunt force thoracic injuries and was pronounced deceased at a trauma center. The patient sustained multiple blunt force injuries and was pronounced deceased at the scene. The paramedic sustained head and chest injuries and was transported by ground ambulance to a trauma center in critical/stable condition. Subsequent police investigation determined that the ambulance driver was incapacitated by a medical episode prior to the crash, thus allowing the vehicle to drift onto the right shoulder to the impact.</p>			
<p>17. Key Words Ambulance crash Ford E350 Fatal Type III</p>		<p>18. Distribution Statement General Public</p>	
<p>19. Security Classif. (of this report) Unclassified</p>	<p>20. Security Classif. (of this page) Unclassified</p>	<p>21. No. of Pages 20</p>	<p>22. Price</p>

TABLE OF CONTENTS

BACKGROUND 1

SUMMARY 2

VEHICLE DATA 2

1998 FORD E350 AMBULANCE 2

2006 GMC K3500 WORK TRUCK 2

AMBULANCE COMPANY AND PERSONNEL 3

PATIENT AND TRANSPORT DETAILS 3

CRASH SITE 4

CRASH SEQUENCE 4

PRE-CRASH 4

CRASH 4

POST-CRASH 5

1998 FORD E350 TYPE III AMBULANCE 6

EXTERIOR DAMAGE 6

2006 GMC K3500 WORK TRUCK 6

EXTERIOR DAMAGE 6

1998 FORD E350 TYPE III AMBULANCE 7

INTERIOR DAMAGE 7

FRONTAL AIR BAG SYSTEM 8

SAFETY BELT SYSTEM 9

PATIENT COMPARTMENT 10

PATIENT COT 12

DRIVER DEMOGRAPHICS 13

DRIVER INJURIES 13

DRIVER KINEMATICS 14

PARAMEDIC DEMOGRAPHICS 15

PARAMEDIC INJURIES 15

PARAMEDIC KINEMATICS 16

PATIENT DEMOGRAPHICS 17

PATIENT INJURIES 17

PATIENT KINEMATICS 19

CALSPAN ON-SITE AMBULANCE CRASH INVESTIGATION
SCI CASE NO: CA09076
VEHICLE: 1998 FORD E350 TYPE III AMBULANCE
LOCATION: TENNESSEE
CRASH DATE: OCTOBER, 2009

BACKGROUND

This on-site investigation focused on the front-to-rear crash of a 1998 Ford E350 Type III ambulance and a stopped 2006 GMC K3500 work truck. The ambulance was conducting a non-emergency transport of a 78-year-old female patient from a dialysis treatment back to her assisted-living-center home at the time of the crash. The restrained 36-year-old male driver and the patient were fatally injured. The unrestrained 51-year-old male paramedic seated on the right bench seat within the patient compartment sustained severe injuries. **Figure 1** is an on-scene image of the crash site taken by the investigating police department.



Figure 1: On-scene image of the vehicles at final rest. Image obtained from investigating police.

The crash occurred during the daylight hours in clear weather conditions. The ambulance had traveled from on an on-ramp and had just merged onto a northbound interstate. It was in the outboard lane. The work truck was stopped on the right shoulder on the east side of the interstate. The ambulance drifted onto the shoulder, impacted and underrode the back of the truck. The ambulance sustained severe frontal damage as a result of the impact. The frontal air bags in the ambulance deployed. The ambulance driver sustained fatal blunt force thoracic injuries and was pronounced deceased at a trauma center. The patient sustained multiple blunt force injuries and was pronounced deceased at the scene. The paramedic sustained head and chest injuries and was transported by ground ambulance to a trauma center in critical/stable condition. Subsequent police investigation determined that the ambulance driver was incapacitated by a medical episode prior to the crash, thus allowing the vehicle to drift onto the right shoulder to the impact.

Notification of the crash was forwarded to the Calspan Special Crash Investigations team by the Crash Investigation Division of the National Highway Traffic Safety Administration (NHTSA) on October 23, 2009. Calspan SCI initiated follow-up investigation and established cooperation with the investigating police on October 28, 2009. On on-site investigation of the crash was assigned on October 29, 2009. The vehicles were impounded by the investigating police agency. At the request of the police investigator, the on-site investigation was delayed until the conclusion of the police investigation. The on-site investigation took place January 5 and 6, 2010.

SUMMARY

VEHICLE DATA

1998 Ford E350 Ambulance

The 1998 Ford E350 chassis was manufactured as an incomplete vehicle in April 1998 and was identified by the Vehicle Identification Number (VIN): 1FDSE30FWHB (production sequence deleted). The Ford E350 was configured on a 351 cm (138 in) wheelbase with a single wheel rear axle. It had a Gross Vehicle Weight Rating (GVWR) of 4,354 kg (9,600 lb). The mileage was unknown. The power train consisted of a 5.4 liter/V-8 diesel engine linked to a four-speed automatic transmission. The service brakes were a front disc/rear drum system without antilock. The manufacturer's recommended tire size was LT245/75R16. The recommended cold tire pressure was 379 kPa (55 PSI) front and 552 kPa (80 PSI) rear. The ambulance was equipped with Michelin LTX LT245/75R16 tires and the specific data measured at the time of the SCI inspection was as follows:

Tire	Measured Pressure	Tread Depth	Restricted	Damage
LF	Tire flat	10 mm (12/32 in)	Yes	None
LR	345 kPa (50 PSI)	9 mm (11/32 in)	No	None
RF	Tire flat	9 mm (11/32 in)	Yes	Wheel separated, Tire debaded
RR	276 kPa (40 PSI)	10 mm (12/32 in)	No	None

The Type III patient compartment of the ambulance was manufactured by McCoy Miller in June 1998. The curb weight of the ambulance was listed as 3,749 kg (8,265 lb). The ambulance could carry a payload of 605 kg (1,335 lb). The patient compartment had a typical layout with a double-rear door for cot loading, a three-passenger bench seat along the right side, a right side entry door, a rear-facing paramedic seat behind the driver and multiple cabinets for storage. The police investigation weighed the ambulance with a set of certified scales and determined its post-crash weight to be 3,379 kg (7,450 lb), excluding occupants.

2006 GMC K3500 Work Truck

The 2006 GMC K3500 work truck was identified by the VIN: 1GDJK34DX6E (production sequence deleted). The GMC was manufactured as an incomplete chassis-cab vehicle with a 348 cm (137.0 in) wheelbase. The four-wheel drive, regular cab truck had a GVWR of 5,443 kg (12,000 lb). The power train consisted of a 6.0-liter diesel engine and 5-speed automatic transmission. The service brakes were four-wheel disc with anti-lock. The truck was outfitted with a 272 cm x 218 cm x 183 cm (107 in x 86 in x 72 in) utility work box (length x width x height). The utility box was manufactured by Knapheide Manufacturing Company. The vehicle was loaded with tools and equipment to assist disabled motor vehicles and it was parked on the side of the road at the time of the crash. During the course of the police investigation, the GMC was weighed with a set of certified scales. The post-crash weight of the truck was determined to be 5,103 kg (11,250 lb) inclusive of tools and equipment. This value did not include the weight of the driver.

AMBULANCE COMPANY AND PERSONNEL

The involved ambulance company was a private medical transport company that provided both non-emergency patient transport services and 9-1-1 emergency response within its Tennessee based region. At the time of the crash, the ambulance was conducting a non-emergency patient transport.

The driver of the ambulance was a 36-year-old male with a reported height and weight of 178 cm (70 in) and 103 kg (226 lb). He was employed as a full-time firefighter and had nine years of service. His employment with the ambulance company was a city-approved second job. The driver had finished a 24-hour shift with the fire department at 0600 hours on the day of the crash. During the evening/night before the crash, the driver's co-workers at the fire department reported that there were no calls and that the driver went to bed at an unknown time after 2200 hours. The driver awoke at 0545 hours and began a 24-hour shift with the ambulance company at 0700 hours. His activities between the start of his shift and the time of the crash are not known.

The driver of the ambulance had a prior medical history with diagnoses of narcolepsy and epilepsy. He was prescribed Adderall for the narcolepsy and Depakote for the epilepsy. His post-mortem toxicology report was positive for the Adderall; however, the quantity of Depakote in his system was below the therapeutic level. Traffic records indicated that the driver had a motor vehicle crash in December 1999 that was related to a seizure and he had his driver license suspended for a three-month period. His fellow firefighters also reported that he had had a seizure approximately three to four years prior to the crash and was placed on light duty activities for an unknown time period.

The paramedic was a 51-year-old male with a height and weight of 178 cm (70 in) and 86 kg (190 lb). He was also employed full-time as a firefighter and his paramedic duties with the ambulance company were a second job. He was seated on the right side bench seat in the patient compartment monitoring the patient at the time of the crash.

PATIENT AND TRANSPORT DETAILS

The crash occurred during the non-emergency transport of the 78-year-old female. She was being transported from a dialysis treatment center to her assisted living-center residence. She had a reported height and weight of 152 cm (60 in) and 71 kg (157 lb) and was being transported on a Stryker MX-Pro cot. The patient was secured to the cot by three lateral restraints with the back rest slightly elevated for comfort. The manner and tightness of the restraints was unknown. The restraints appeared to be located across the lower extremities, abdomen and chest based on the on-scene images. The cot was not damaged during the crash and was removed from the scene by the ambulance company. It was placed back in service the day following the crash. The cot was not inspected for this SCI investigation.

CRASH SITE

This two-vehicle crash occurred during the daylight hours of October 2009. At the time of the crash, the weather was not a factor. The crash occurred on a 5-lane interstate highway within the city limits. The road was straight and level in the area of the crash. Approximately 0.8 km (0.5 mile) south of the crash site, the two outboard lanes of the interstate had merged with the three inboard lanes forming the 5-lane interstate. The ambulance was northbound in the outboard lane. The width of the asphalt shoulder outboard the right-most lane measured 3.6 m (11.8 ft). The east roadside consisted of grass terrain. The speed limit in the area of the crash was 89 km/h (55 mph). **Figure 2** is a northward view of the crash site at the point of impact.



Figure 2: Northward view of the point of impact.

CRASH SEQUENCE

Pre-Crash

Immediately prior to the crash, the ambulance was conducting the non-emergency transport of the 78-year-old female patient from a dialysis treatment center to her assisted living center residence. The patient was restrained in a semi-reclined position on the cot that was secured in the patient compartment. The unrestrained 51-year-old male paramedic was seated on the center aspect of the right bench seat monitoring the patient. Along its route of travel, the ambulance travelled from an eastbound interstate highway and merged onto a northbound interstate. The ambulance was northbound in the outboard lane driven by the 36-year-old restrained male. The GMC work truck was stopped and parked on the right shoulder of the interstate facing north. The GMC was driven by a 60-year-old male.

The ambulance drifted to the right, onto the shoulder, to impact with the back plane of the GMC. There was no evidence of pre-crash braking or evasive steering by the ambulance driver. The 60-year-old driver of the GMC work truck indicated that he had just stopped, placed the transmission into park, and released his safety belt when the crash occurred. **Figure 20**, attached to the end of this report, is a schematic of the crash.

Crash

The front plane of the ambulance struck the back plane of the GMC in a right offset configuration. A reconstruction of the impact configuration determined the centerline of the ambulance was 51 cm (20 in) right of the centerline of the GMC. The direction of force was in the 12 and 6 o'clock sectors for the ambulance and GMC, respectively. As the front of the ambulance crushed, the vehicle pitched down and the right frame rail underrode the GMC. The area of the impact was evidence by gouge marks in the asphalt shoulder.

The momentum of the ambulance accelerated the GMC forward and the offset configuration resulted in a counterclockwise (CCW) rotation. The GMC was displaced forward and rotated

170 degrees CCW across the shoulder. The vehicle came to rest in the outboard northbound lane, 17 m (56 ft) north of the point of impact. Its post-impact movement was evidenced by three arcing tire marks, **Figure 3**. The driver then moved the GMC to its post-crash location on the right shoulder of the roadway. The ambulance continued along its northeast trajectory and came to rest on the east roadside 18 m (59 ft) from the impact. Its post-crash trajectory was evidenced by two parallel gouge marks in the roadside terrain, **Figure 4**.



Figure 3: View of the post-crash tire marks defining the trajectory of the GMC.



Figure 4: View of the point of impact and post-crash trajectory of the ambulance.

The Damage Algorithm of the WinSMASH program was used to determine the severity of the crash (delta-V). This analysis was considered to be borderline and the results underestimated the crash severity. The severity was underestimated due to the use of the default stiffness values of a GMC pickup truck as a substitute for the unknown stiffness of the involved GMC work truck. The total delta-V of the ambulance was 45.0 km/h (28.0 mph). The longitudinal and lateral components were -44.3 km/h (-27.5 mph) and -7.8 km/h (-4.8 mph), respectively. The total delta-V of the GMC was 33.0 km/h (20.5 mph) with longitudinal and lateral components of 32.5 km/h (20.2 mph) and 5.7 km/h (3.5 mph), respectively. The Barrier Equivalent Velocity of the ambulance 55.5 km/h (34.5 mph). An in-line momentum calculation of the crash determined the impact speed of the ambulance was 100 km/h (62 mph) with a delta-V of 58 km/h (36 mph).

Post-Crash

The police, ambulance, and fire personnel responded to the scene. The driver of the ambulance was removed from the vehicle by the first responders. He was transported to a trauma center with blunt force thoracic injuries and was pronounced dead upon arrival. An autopsy was performed the day following the crash. The female patient was displaced from the cot during the impact and was found in the right side entry of the patient compartment. She sustained multiple fatal blunt force injuries. An autopsy was performed the day following the crash. The paramedic was displaced from the right bench seat and impacted the cabinet located at the forward right aspect of the patient compartment. He sustained head and chest injuries. He was located within the right entry way on top of the patient. The paramedic was transported in critical, but stable, condition and hospitalized for a period of 18 days.

1998 FORD E350 TYPE III AMBULANCE

Exterior Damage

The forward aspect of the ambulance sustained severe impact damage as a result of the impact with the back plane of the GMC. **Figures 5 through 7** are the front, left and right views of the ambulance cab. The depth of the crush extended nearly to the left A-pillar area. The cab was compressed into the forward wall of the patient compartment and the ambulance frame buckled. The front bumper separated from the frame rails during the impact. The width of the direct contact damage measured 155 cm (61.0 in), beginning 69 cm (27.2 in) right of center and extended to the left front corner. The forward aspect of the left frame rail crushed 35 cm (13.8 in) and buckled. The right frame rail underrode the back plane of the GMC and was undamaged. A crush profile was measured along the vertical face of the ambulance originally located immediately above the bumper. The residual crush profile was as follows: C1 = 89 cm (35.0 in), C2 = 79 cm (31.1 in), C3 = 69 cm (27.2 in), C4 = 47 cm (18.5 in), C5 = 37 cm (14.7 in), C6 = 15 cm (5.9 in). The left fender was completely crushed. The left A-pillar was in a near vertical orientation. The roof buckled vertically 23 cm (9.0 in) at the left door opening. The width of the left door crushed 13 cm (5.0 in) and it buckled outboard. The door was removed by the first responders to access the driver. The right front door was jammed closed. The left wheelbase was reduced 20 cm (8.0 in). The right front suspension fractured during the impact and the wheel/tire separated. The Collision Deformation Classification (CDC) was 12-FDAW6.



Figure 5: Front view of the ambulance



Figure 6: Left view depicting the extent of crush.




Figure 7: Right view of the ambulance.

2006 GMC K3500 WORK TRUCK

Exterior Damage

The GMC K3500 Work Truck sustained moderate severity damage as a result of the impact (**Figure 8 and 9**). The damage was biased to the right due to the offset impact configuration.

The direct contact damage began 34 cm (13.5 in) left of center and extended 144 cm (56.5 in) to the right corner of the bumper. Within the damaged region, the height of the direct contact on the back plane of the truck measured 191 cm (75 in) above the ground. The residual crush profile along the rear bumper of the truck was as follows: C1 = 0, C2 = 0, C3 = 11 cm (4.3 in), C4 = 27 cm (10.6 in), C5 = 34 cm (13.4 in), C6 = 50 cm (19.7 in). The right wheelbase was reduced 6 cm (2.5 in). The left wheelbase was unchanged. There was contact between the forward right corner of the utility box and the right aspect of the cab. The cab's right door frame overlapped the right B-pillar structure 3 cm (1.0 in). The backlight of the cab was disintegrated. The CDC was 06-BDEW3.



Figure 8: View of the GMC's back plane.



Figure 9: Right view depicting the extent of crush.

1998 FORD E350 TYPE III AMBULANCE

Interior Damage

The interior of ambulance cab sustained severe intrusion as a result of the frontal crash. **Figure 10** is a left lateral view of the ambulance cab. The box-mounted driver seat was adjusted to the full-rear track position and was jammed in place. The seat track travel of an exemplar vehicle measured 19 cm (7.5 in). The seat back angle measured 10 degrees aft of vertical. The horizontal distance from the seat back to the driver air bag module in the center of the steering wheel measured 46 cm (18.1 in). The adjustment of the two-spoke, tilt steering wheel was unknown. In its undamaged condition the driver air module is located approximately 1 cm (0.5 in) forward of the plane of the steering wheel rim. At inspection, the driver air bag module/inflator hub protruded 8 cm (3 in) aft of the plane of the steering wheel. As the driver loaded the deployed air bag and steering wheel rim during the crash, the steering column was displaced rearward (through the plane of the rim) due to the extent of the crush. There was no separation of the steering column's shear capsules from the intruded instrument panel.



Figure 10: Left lateral view of the ambulance cab.

The instrument panel, steering wheel/column, knee bolster and associated components deformed rearward into the driver's occupant space. The magnitudes of the longitudinal intrusion are identified in the table below:

Position	Component	Intrusion
Row 1 Left	Windshield Header	19 cm (7.5 in)
Row 1 Left	A-Pillar	30 cm (12.0 in)
Row 1 Left	Steering Column	27 cm (10.5 in)
Row 1 Left	Instrument Panel	27 cm (10.5 in)
Row 1 Left	Knee Bolster	18 cm (7.0 in)
Row 1 Left	Toe Pan	39 cm (15.5 in)

Frontal Air Bag System

The 1998 Ford E-350 was equipped with a redesigned frontal air bag system for the driver and front right positions. As a result of the frontal impact, the air bag system deployed. The driver's air bag was conventionally located in the center of the steering wheel hub and was concealed by two cover flaps. The top cover flap measured 19 cm (7.5 in) in height and 13 cm (5 in) in width. The lower cover flaps measured 6 cm (2.5 in) in height and 13 cm (5 in) width. **Figure 11** is an overall view of the driver air bag. The air bag measured 61 cm (24 in) in diameter in its deflated deployed state. The air bag contained two tethers at the 12 and 6 o'clock positions and was vented by two vent ports at the 11 and 1 o'clock positions. The air bag contained a heavy concentration of body fluids in the 2 to 5 o'clock sectors. The 6 o'clock sector of the air bag was captured between the steering wheel rim and the intruded knee bolster.

Most significant in the inspection of the driver air bag was that the inflator had melted through the center aspect of the face of the air bag. **Figure 12** is a close-up view of the inflator. Blue fabric from the driver's shirt adhered to the inflator's top surface. During the impact, as the driver loaded the deployed air bag and compressed the steering wheel, the steering column intruded rearward and compressed against the driver. At final rest, the driver was slumped forward against the steering wheel and deflated air bag. The hot air bag inflator contacted and melted the face of the air bag. The driver's shirt was burned and melted. The autopsy record identified a burn injury to his left upper chest.



Figure 11: View of the deployed driver air bag.



Figure 12: Close-up view of the driver air bag inflator visible through the face of the melted air bag.

The front right air bag was a top-mount design incorporated into the right aspect of the instrument panel. The air bag was concealed by a single cover flap that measured 29 cm (11.5 in) in height and 39 cm (15.5 in) in width. The rectangular shaped air bag membrane measured 91 cm (36 in) in height and 46 cm (18 in) in width. The air bag contained two vent ports on the side panels. The air bag membrane was free of damage and occupant contacts.

Safety Belt System

The 1998 Ford E350 was equipped with manual 3-point lap and shoulder safety belts for the two seating positions. The driver's safety belt was configured with continuous loop webbing, a sliding latch plate, a height adjustable D-ring, an Emergency Locking Retractor (ELR), and a buckle-mounted pretensioner. The D-ring was adjusted to the full-down position at the time of the SCI inspection. The buckle pretensioner had actuated during the impact evidenced by buckle stalk compression. The latch plate was still buckled into the receiver and a 124 cm (49 in) length of webbing was threaded through the latch plate. The first responders had cut the webbing in order to remove the driver from the vehicle. The webbing was cut immediately above the sleeve at the outboard anchor and at a position 56 cm (22 in) above the latch plate. This webbing section was creased at the latch plate. At the D-ring, a 10 cm (4 in) section of the webbing was observed to be heat-stressed and brittle. Melted fabric from the air bag was fused to the webbing. **Figure 13** is a view of the shoulder belt webbing and melted air bag fabric. This section of the belt contacted the driver air bag and the hot inflator when the driver was slumped forward at final rest. The hot inflator melted the air bag fabric and belt webbing. When the webbing was cut by the first responders, the melted section was captured in the D-ring



Figure 13: View of the driver's safety belt webbing at the D-ring.

as the retractor spooled in the slack belt. The SCI observations of the belt system during the inspection determined the driver was restrained at the time of the crash.

The front right safety belt was configured with continuous loop webbing, sliding latch plate, height adjustable D-ring, a switchable ELR/Automatic Locking Retractor (ALR) and a buckle pretensioner. The front right seat was not occupied during the crash. The right buckle pretensioner had also actuated during the impact.

PATIENT COMPARTMENT

The exterior of the ambulance's patient compartment was not damaged during the crash. There were two exterior storage compartments located on each side of the ambulance. All the doors of the exterior compartments were operational. A 127 cm (50 in) tall H-size oxygen cylinder was located in the compartment at the left rear aspect of the ambulance. The cylinder was secured in place by a single ratchet-style load strap at the mid-upper aspect. The tank remained secured during the impact.

Figure 14 is a view into the patient compartment through the rear doors. There was no interior damage to the left, rear or right side walls and cabinetry. The interior was constructed of plywood overlaid with composite panels and aluminum trim. The cabinets had fore/aft sliding plexiglass doors with friction closures. The box-mounted rear-facing jump seat was located at the forward wall, behind the driver's position. The cushion of the seat appeared to have been loaded by the patient and/or loose objects during the crash. The floor-mounted antler bracket and rail clamp that secured the cot in its transport position were not damaged.

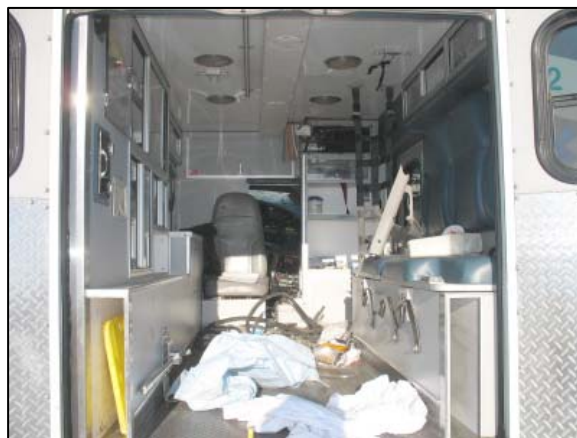

Figure 14: Rear view into the patient compartment.

The paramedic was seated on the center position of side facing bench. An on-scene police image depicted that a cardiac monitor was located at the forward aspect of the bench. A vertical-oriented net restraint was located at the forward end of the bench. The net restraint measured 30 x 122 cm (12 x 48 in) and was comprised of five horizontal straps woven to three vertical straps. Each strap was 5 cm (2 in) wide. The ends of the vertical straps were sewn into loops. A metal pull-handle was placed through each loop and the pull-handle was attached to the ceiling and the base cabinet of the bench seat by wood screws. During the impact, the paramedic was displaced forward by the impact force and into the netting. His loading force into the net was distributed to the roof and cabinet through the fastener connections. It was observed that the wood screws in the ceiling had partially pulled out and that the inboard cabinet joint, adjacent to the net, had fractured from his loading. Refer to **Figures 15 and 16**.



Figure 15: View of the net restraint.



Figure 16: View of the fractured base cabinet as a result of the net restraint loading.

A 170 x 71 cm (67 x 28 in) three-shelf cabinet was located at the forward right aspect of the patient compartment. The upper inboard corner of this cabinet was fractured by contact from the displaced patient and paramedic (**Figure 17**). The entire cabinet was also displaced forward 5 cm (2 in), measured at its inboard corner. The aluminum trim surrounding the shelves and corners was abraded. The paramedic's hat was found within the fractured top shelf area. A 22 x 25 in area of body fluid spatter was located on the forward wall, left of the fractured cabinet, **Figure 18**.



Figure 17: Forward cabinet fractured by occupant contact.



Figure 18: View of the fractured cabinet and fluid evidence.

The final rest position of the patient and paramedic was evidenced by a 76 x 64 cm (30 x 25 in) area of body fluid located in the right entry. There was a sliding drawer incorporated into the forward aspect of the right bench. During the crash, this drawer slid open in response to the impact force and was displaced from its tracks. It was found in the right entry post-crash. The police images depicted the final rest of the patient in contact with the displaced drawer.

PATIENT COT

The cot used to transport the patient in this crash was a Stryker MX-PRO. It was not damaged during the crash event. **Figure 19** is a police image of the cot. The cot was not damaged during the crash. It was moved out of the patient compartment by the first responders prior to the arrival of the police investigator. At the conclusion of the on-scene police investigation, the cot was removed from the crash site by the ambulance company. The cot was placed back in service the day following the crash and was not inspected for this SCI investigation.



Figure 19: Police supplied image of the Stryker cot.

The cot was constructed of steel tubing with a scissor design lower frame which allowed for height adjustment. The angle of the back rest was set via a pneumatic adjustment. The specific angle of the back rest at the time of the crash was not known. When secured in the ambulance for transport, the frame work supporting the cot's front wheels nested in the antler bracket that was attached to the ambulance floor. A locking pin attached to the tubular frame between the right wheels was captured by the floor mounted rail clamp. As stated earlier in this report, the cot remained engaged in the antler bracket and the clamp throughout the crash sequence.

The cot contained a three belt system for securing patients. Each restraint consisted of two adjustable length webbings with a locking latch plate. The fixed end of each webbing was attached to the side frame of the cot.

DRIVER DEMOGRAPHICS

Age/Sex: 36-year-old/Male
 Height: 178 cm (70 in)
 Weight: 103 kg (226 lb)
 Seat Track Position: Full-rear track position
 Eyewear: None
 Safety Belt Usage: 3-point manual lap and shoulder safety belt
 Usage Source: SCI vehicle inspection
 Egress from Vehicle: Removed from vehicle
 Mode of Transport from Scene: Ground ambulance to a Level 1 trauma center
 Type of Medical Treatment: None - fatally injured

DRIVER INJURIES

Injury	Injury Severity (AIS 90/Update 98)	Injury Source
Laceration of the heart, at the base with near avulsion. (Includes a tricuspid valve injury)	Maximum (441014.6,4)	Steering wheel/column
Bilateral flail chest (all ribs are fractured bilaterally and many in multiple locations) with bilateral lung contusions	Critical (450266.5,3)	Steering wheel/column
Lacerations of the pleural surfaces (with hemothorax)	Moderate (441802.3,9)	Steering wheel/column
Cervical fracture of C1 with separation, NFS	Moderate (650216.2,6)	Non-contact - head motion
Cervical fracture of C2 with separation, NFS	Moderate (650216.2,6)	Non-contact - head motion
Multiple superficial lacerations of the liver	Moderate (541822.2,1)	Safety belt
Charring of the skin in the upper left chest and left shoulder (15cm area)	Moderate (992008.2,2)	Driver air bag inflator
Center chest contusion	Minor (490402.1,4)	Safety belt
Center chest, multiple small abrasions measuring between 0.6cm and 2.5 cm in dimension each	Minor (490202.1,4)	Safety belt
Right upper quadrant abdominal contusions (1.9 cm contusion near the costal margin and a 13cm obliquely oriented linear contusion parallel to the right costal margin)	Minor (590402.1,1)	Steering wheel rim
Right upper quadrant abdominal abrasion (1.9cm near the costal margin)	Minor (590202.1,1)	Steering wheel rim
Left upper arm contusion, lateral aspect, 6.3cm x 2.5cm	Minor (790404.1,2)	Instrument panel

Injury	Injury Severity (AIS 90/Update 98)	Injury Source
Left anterior forearm, 7.6cm x 5cm patterned contusion	Minor (790402.1,2)	Instrument panel
Left knee abrasion, 3.1cm x 1.3cm (on the anterior aspect)	Minor (890202.1,2)	Knee bolster
Left knee laceration, 3.1cm x 1.3cm (on anterior aspect)	Minor (890602.1,2)	Knee bolster
Left lower extremity laceration, 6.3cm x 3.1cm (anterior aspect)	Minor (890602.1,2)	Knee bolster
Left lower extremity abrasion 3.1cm x 2.5cm (near the superior margin)	Minor (890202.1,2)	Knee bolster
Left lower extremity abrasions, lower portion, anterior aspect 1.28cm and 1.9cm in dimension each	Minor (890202.1,2)	Knee bolster
Right knee abrasions (maximum of 2.5cm each)	Minor (890202.1,1)	Knee bolster
Right knee contusions (maximum of 2.5cm each)	Minor (890402.1,1)	Knee bolster
Right knee lacerations (maximum of 2.5cm each)	Minor (890602.1,1)	Knee bolster
Right lower extremity contusion, 5cm on the anterior aspect	Minor (890402.1,1)	Knee bolster
Right lower extremity abrasion, 5cm x 4.4cm “V”shaped abrasion on the inner aspect near the knee	Minor (890202.1,1)	Knee bolster
Right lower extremity abrasion, 2.5cm on the anterior aspect near the ankle	Minor (890202.1,1)	Toe pan

Source: Autopsy report

DRIVER KINEMATICS

The 36-year-old restrained male was seated in a full-rear track position. His pre-crash posture was unknown due to a pre-crash medical episode that precipitated the crash. The driver had a diagnosed history of epilepsy and narcolepsy and was taking prescription medication. The post-mortem toxicology report indicated the level of Depakote in his system was below the therapeutic level for the control of his epilepsy.

At impact, the safety belt retractor locked, the pretensioner actuated and the driver air bag deployed. The actuated buckle pretensioners removed potential slack within the belt system. The driver initiated a forward trajectory in response to the 12 o'clock direction of the impact. The driver loaded the locked safety belt and deployed driver air bag and began to ride down the force of the crash. His lower extremities contacted the knee bolster. Coincident with the driver's forward kinematic pattern and loading, the steering wheel/column, instrument panel and knee bolster intruded into the driver's occupant space. The driver loaded through the air bag and bottomed out the bag on the steering wheel rim and column. As the steering wheel/column intruded, the column rotated to a more vertical orientation and the driver's head was forced into

flexion resulting in the high cervical fracture. The driver’s chest loading resulted in the fatal blunt force thoracic injuries identified in the table above. The lower extremities injuries were attributed to contact with the knee bolster. At final rest, the driver was slumped forward over the top of the steering wheel and column. This forward position caused the deflated driver air bag to contact the hot inflator. The hot inflator melted through the face of the air bag and caused a burn injury to the driver’s left upper chest. The driver was removed from the vehicle by the first responders, transported to a trauma center and pronounced deceased.

PARAMEDIC DEMOGRAPHICS

Age/Sex: 51-year-old/Male
 Height: 178 cm (70 in)
 Weight: 86 kg (190 lb)
 Seat Position: Side-facing bench seat on right wall of patient compartment
 Eyewear: None
 Safety Belt Usage: None
 Usage Source: SCI vehicle inspection
 Egress from Vehicle: Assisted due to serious injuries
 Mode of Transport from Scene: Ground ambulance to a Level 1 trauma center
 Type of Medical Treatment: Hospitalized 18 days

PARAMEDIC INJURIES

Injury	Injury Severity (AIS 90/Update 98)	Injury Source
Left side rib fractures 1 thru 5, (Left ribs 1 and 2 are displaced, Left ribs 4 and 5 have an overlap of fracture fragments) with moderate sized pneumothorax on the left side	Severe (450252.4,2)	Patient compartment interior cabinet
Right frontoparietal region subtle sulcal subarachnoid hemorrhage	Serious (140684.3,1)	Patient compartment interior cabinet
Left side pulmonary contusion	Serious (441406.3,2)	Patient compartment interior cabinet
Right distal radius fracture, comminuted	Serious (752804.3,1)	Ambulance floor
Right distal ulna shaft fracture, comminuted	Serious (753204.3,1)	Ambulance floor
C7 lamina fracture	Serious (650224.3,6)	Patient compartment interior cabinet
C7 pedicle fracture	Serious (650226.3,6)	Patient compartment interior cabinet
Right mandible condyle comminuted fracture	Moderate (250616.2,1)	Patient compartment interior cabinet
Tempomandibular joint (TMJ) dislocation	Moderate (251604.2,1)	Patient compartment interior cabinet
C1 right transverse process fracture	Moderate (650220.2,6)	Patient compartment interior cabinet

Injury	Injury Severity (AIS 90/Update 98)	Injury Source
C5 left transverse process fracture	Moderate (650220.2,6)	Patient compartment interior cabinet
C6 left transverse process fracture	Moderate (650220.2,6)	Patient compartment interior cabinet
C7 right transverse process fracture (comminuted)	Moderate (650220.2,6)	Patient compartment interior cabinet
C7 vertebral body fracture (posterolateral aspect)	Moderate (650230.2,6)	Patient compartment interior cabinet
T2 left transverse process fracture	Moderate (650420.2,7)	Patient compartment interior cabinet
Left adrenal gland hematoma	Minor (540210.1,2)	Patient compartment interior cabinet
Left parietal scalp hematoma	Minor (190402.1,2)	Patient compartment interior cabinet
8 cm apex of scalp laceration	Minor (190600.1,5)	Patient compartment interior cabinet
6 cm posterior scalp laceration	Minor (190600.1,6)	Patient compartment interior cabinet
3 cm anterior tongue laceration	Minor (243402.1,8)	Self-inflicted
Small forehead laceration NFS	Minor (290602.1,7)	Patient compartment interior cabinet
Left lateral orbital area laceration, (1-2 cm adjacent to left eye)	Minor (297602.1,2)	Patient compartment interior cabinet
Left forehead abrasion	Minor (290202.1,7)	Patient compartment interior cabinet
Left supraorbital abrasion	Minor (297202.1,2)	Patient compartment interior cabinet

Source: Hospitalization discharge summary

PARAMEDIC KINEMATICS

The unrestrained 51-year-old paramedic was seated on the center aspect of the side-facing bench seat in the patient compartment of the ambulance. He was facing the left side of the ambulance monitoring the patient. At impact, the paramedic was displaced to his right (forward with respect to the vehicle) in response to the 12 o'clock direction of the impact force. He contacted the safety net located at the end of the bench seat with his right flank. His contact to the netting was evidenced by the fractured bench cabinet at the lower anchors of the safety net and loading to the fasteners anchoring the safety net to the roof. This loading decelerated the paramedic and allowed the displaced patient time to move further forward and ahead of the paramedic (with respect to their relative positions within patient compartment).

The paramedic rotated clockwise around the net and continued his forward trajectory. The paramedic's head, left flank and back contacted the upper portion of the cabinet located at the front right aspect of the patient compartment. This contact resulted in the multiple soft tissue,

head, and thoracic injuries. As the paramedic rotated, the patient's torso and lower extremities were also being displaced into the lower aspect of the cabinet at the front right aspect of the patient compartment. It was probable that the paramedic also had occupant to occupant interactions with the patient, forcing her into accentuated contact with cabinet.

The paramedic then rebounded from the cabinet onto the floor and onto the patient. His right forearm was fractured by the floor contact. The paramedic was found in the front right aspect of the patient compartment on top of the patient. He was removed by the first responders and transported to a trauma center in critical but stable condition and hospitalized for 18 days.

PATIENT DEMOGRAPHICS

Age/Sex: 78-year-old/Female
 Height: 152 cm (60 in)
 Weight: 71 kg (157 lb)
 Seat Position: Supine on a cot in a rear facing mode, back rest slightly elevated for comfort
 Eyewear: None
 Safety Belt Usage: Three separate manual lap belts; across chest, abdomen and legs
 Usage Source: Paramedic interview
 Egress from Vehicle: Removed from vehicle
 Mode of Transport from Scene: Ground ambulance
 Type of Medical Treatment: None, fatally injured

PATIENT INJURIES

Injury	Injury Severity (AIS 90/Update 98)	Injury Source
Multiple lacerations of the heart, including both ventricles and the valves	Maximum (441016.6,4)	Patient compartment interior cabinet
Bilateral flail chest (all ribs fractured bilaterally and displaced)	Critical (450266.5,3)	Patient compartment interior cabinet
Laceration of the aorta	Severe (420206.4,4)	Patient compartment interior cabinet
Multiple lacerations of the left lung	Serious (441430.3,2)	Patient compartment interior cabinet
Multiple lacerations of the pleural surfaces (with hemothorax)	Serious (441802.3,9)	Patient compartment interior cabinet
Partial degloving of the right hand	Serious (794006.3,1)	Unknown
Multiple lacerations of the left lobe of the liver	Moderate (541820.2,1)	Patient compartment interior cabinet
Multiple lacerations of the spleen	Moderate (544220.2,2)	Patient compartment interior cabinet
Left clavicle fracture	Moderate (752200.2,2)	Jump seat

Injury	Injury Severity (AIS 90/Update 98)	Injury Source
Right clavicle fracture	Moderate (752200.2,1)	Jump seat
C7 fracture NFS	Moderate (650216.2,6)	Jump seat
T6 fracture NFS	Moderate (650416.2,7)	Patient compartment interior cabinet
S1 fracture with dislocations of both iliosacral junctions	Moderate (852600.2,6)	Patient compartment interior cabinet
Scattered small subgaleal hemorrhages (less than 2.5cm)	Minor (190402.1,9)	Jump seat
0.6cm abrasion lateral to left eye	Minor (297202.1,2)	Ambulance floor
5cm laceration to the base of the chin	Minor (290602.1,8)	Ambulance floor
15cm x 8cm contusion to the right upper portion of chest	Minor (490402.1,1)	Ambulance floor
Upper abdomen contusion, 8cm x 3.8cm (near midline)	Minor (590402.1,7)	Ambulance floor
Pattern contusion across the lower portion of the abdomen in a 30cm x 25cm area (consists of 2.5cm x 0.16cm contusions in a grid like pattern)	Minor (590402.1,8)	Ambulance floor
Anterior neck diffuse contusion	Minor (390402.1,5)	Ambulance floor
Posterior neck laceration (1.9cm)	Minor (390602.1,6)	Ambulance floor
Left forearm multiple lacerations NFS (posterior aspect)	Minor (790600.1,2)	Ambulance floor
Left forearm ecchymosis (posterior aspect)	Minor (790402.1,2)	Ambulance floor
Right elbow and forearm multiple lacerations NFS (posterior aspect)	Minor (790600.1,1)	Ambulance floor
Right elbow and forearm ecchymosis (posterior aspect)	Minor (790402.1,1)	Ambulance floor
Bilateral knee abrasions, inner aspects, 2.5cm x 3.8cm on right knee and 2.5cm on left knee	Minor (890202.1,3)	Lateral safety restraint
Left lower extremity (anterior aspect) 15cm x 5cm ecchymosis	Minor (890402.1,2)	Lateral safety restraint

Source: Autopsy report

PATIENT KINEMATICS

The patient was lying supine on a cot that was secured in a rear-facing manner by the antler bracket and floor-mounted rail clamp in the patient compartment of the ambulance. The back rest was slightly elevated for the comfort of the patient. Three lateral restraints secured the patient to the cot. These restraints were reportedly located across the chest, abdomen and lower extremities. The paramedic had no recollection of how tight the restraints were adjusted.

At impact, the patient responded with a forward trajectory in response to the 12 o'clock direction of the impact. The patient slid out from under the lateral restraints and ramped up the back rest. Abrasions were noted to her lower extremities from contact with the restraints. Due to its close proximity, the patient was displaced violently into the jump seat. Her head contacted the seat back and became restrained. The patient's torso then continued loading her neck resulting in the cervical fracture. Her upper back impacted the seat back fracturing the clavicles. The patient's lower torso and legs separated from the cot and her body rotated toward the right front area of the patient compartment. She impacted the lower portion of the cabinet with her chest and abdomen and was loaded from behind by the paramedic. Her contact to the cabinet resulted in the multiple blunt thoracic injuries. The patient was displaced onto the floor and into the right entryway with the paramedic on top of her. Her contact with the floor resulted in multiple soft tissue injuries. The abrasion pattern to the patient's abdomen matched the diamond plate floor pattern. The patient was pronounced deceased at the scene of the crash.

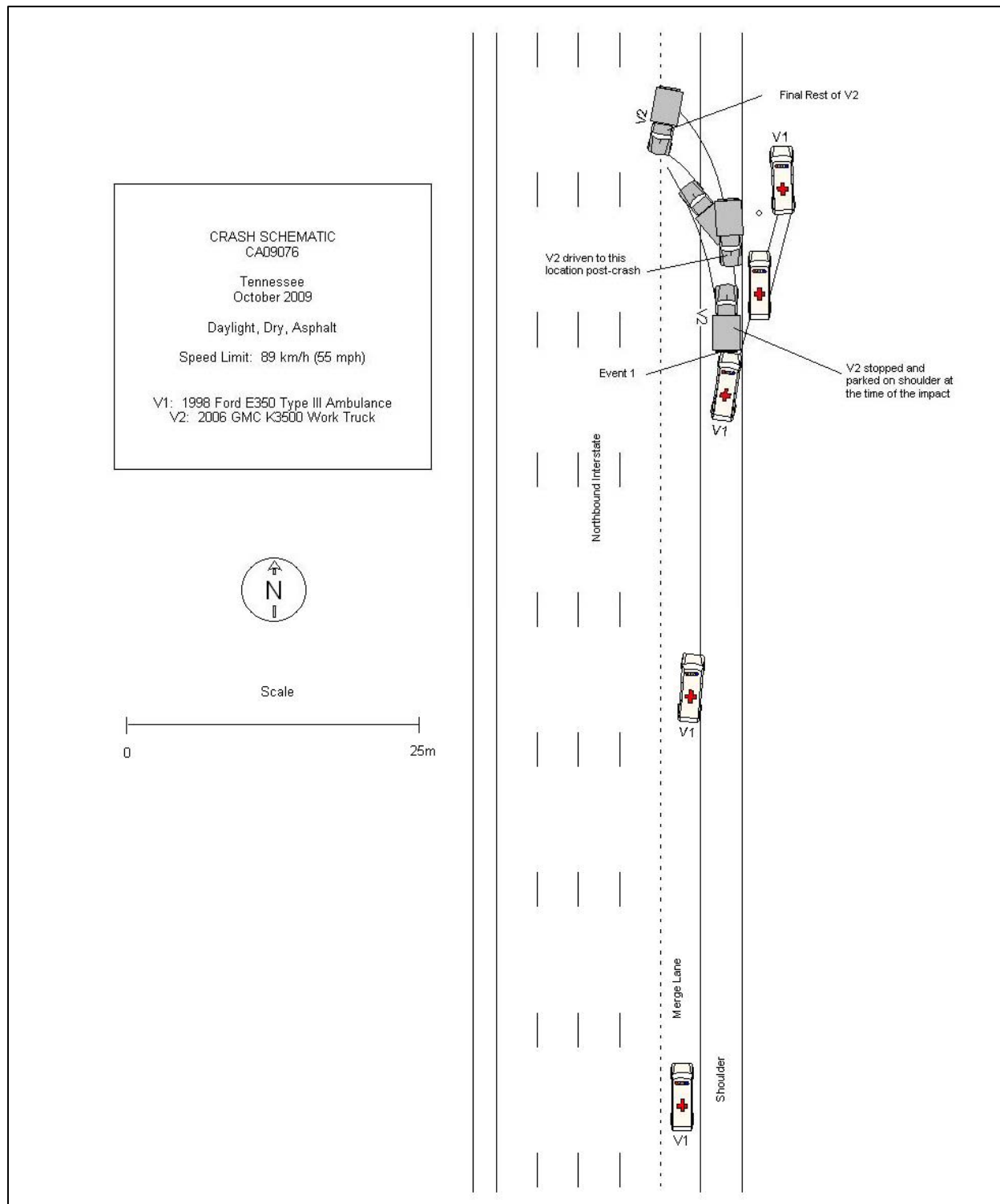


Figure 20: Crash Schematic.