



INDIANA UNIVERSITY

TRANSPORTATION RESEARCH CENTER

School of Public and Environmental Affairs
222 West Second Street
Bloomington, Indiana 47403-1501
(812) 855-3908 Fax: (812) 855-3537

ON-SITE AIR BAG INVESTIGATION

CASE NUMBER - IN97-018
LOCATION - ILLINOIS
VEHICLE - 1994 PLYMOUTH VOYAGER
CRASH DATE - MAY, 1996

Submitted:

April 28, 1999

Revised Submission:

March 18, 2002



Contract Number: DTNH22-94-D-17058

Prepared for:

U.S. Department of Transportation
National Highway Traffic Safety Administration
National Center for Statistics and Analysis
Washington, D.C. 20590-0003

DISCLAIMERS

This document is disseminated under the sponsorship of the Department of Transportation in the interest of information exchange. The United States Government assumes no responsibility for the contents or use thereof.

The opinions, findings, and conclusions expressed in this publication are those of the authors and not necessarily those of the National Highway Traffic Safety Administration.

The crash investigation process is an inexact science which requires that physical evidence such as skid marks, vehicular damage measurements, and occupant contact points be coupled with the investigator's expert knowledge and experience of vehicle dynamics and occupant kinematics in order to determine the pre-crash, crash, and post-crash movements of involved vehicles and occupants.

Because each crash is a unique sequence of events, generalized conclusions cannot be made concerning the crashworthiness performance of the involved vehicle(s) or their safety systems.

1. Report No. IN97-018		2. Government Accession No.		3. Recipient's Catalog No.	
4. Title and Subtitle On-Site Air Bag Fatality Investigation Vehicle - 1994 Plymouth Voyager Location - Illinois			5. Report Date: April 28, 1999; March 18, 2002		
			6. Performing Organization Code		
7. Author(s) Special Crash Investigations Team #2			8. Performing Organization Report No. Task #s 0095 and 0276		
9. Performing Organization Name and Address Transportation Research Center Indiana University 222 West Second Street Bloomington, Indiana 47403-1599			10. Work Unit No. (TRAIS)		
			11. Contract or Grant No. DTNH22-94-D-17058		
12. Sponsoring Agency Name and Address U.S. Department of Transportation (NRD-32) National Highway Traffic Safety Administration National Center for Statistics and Analysis Washington, D.C. 20590-0003			13. Type of Report and Period Covered Technical Report Crash Date: May, 1996		
			14. Sponsoring Agency Code		
15. Supplementary Notes On-site air bag deployment investigation involving a 1994 Plymouth Voyager, minivan, with manual safety belts and dual front air bags, and a 1994 Oldsmobile Cutlass Supreme, two-door coupe.					
16. Abstract This report covers an on-site investigation of an air bag deployment crash that involved a 1994 Plymouth Voyager (Case Vehicle) and a 1994 Oldsmobile Cutlass Supreme (other vehicle). This crash is of special interest because the case vehicle's, improperly restrained, front right passenger (4-year-old female) sustained critical brain and cervical injuries as a result of impacting her front right air bag, resulting in her death. The case vehicle was traveling northwest in the outside lane on a four-lane, divided state trafficway (i.e., both the southeast and northwest roadways had two through lanes; the median was a paved-painted type with varying width). The Oldsmobile had been traveling southeast in the inside lane of the southeast roadway and was attempting a left turn across the northwest roadway into a parking lot driveway. The crash occurred in the outside lane of the northwest roadway in the junction of the driveway. The front of the case vehicle impacted the right side of the Oldsmobile, causing the case vehicle's driver and front right passenger supplemental restraints (air bags) to deploy. The front right passenger in the case vehicle was seated, with her seat track located between its middle and forward-most positions, and was restrained only by the lap belt portion of her available, active, three-point, lap-and-shoulder, safety belt system—having the shoulder belt portion behind her back. She sustained, according to her medical records, critical injuries which included: a severe cerebral edema and a diffuse axonal injury, and dislocations of the cervical vertebrae at C ₁ -C ₂ (atlantoaxial) and C ₂ -C ₃ . The case vehicle's driver (37-year-old female) was seated with her seat track located between its middle and forward-most positions, and the tilt steering wheel was located in its middle position. She was restrained by her available, active, three-point, lap-and-shoulder, safety belt system, and did not sustain any injuries as a result of this crash.					
17. Key Words Air Bag Deployment			Motor Vehicle Traffic Crash Injury Severity		18. Distribution Statement General Public
19. Security Classif. (of this report) Unclassified	20. Security Classif. (of this page) Unclassified		21. No. of Pages 15	22. Price \$9,100	

TABLE OF CONTENTS

IN97-018

Page No.

BACKGROUND 1

SUMMARY 1

CRASH CIRCUMSTANCES 3

CASE VEHICLE: 1994 PLYMOUTH VOYAGER 4

 CASE VEHICLE DAMAGE 4

 AUTOMATIC RESTRAINT SYSTEM 5

 CASE VEHICLE FRONT RIGHT PASSENGER KINEMATICS 7

 CASE VEHICLE FRONT RIGHT PASSENGER INJURIES 9

 CASE VEHICLE DRIVER KINEMATICS 10

 CASE VEHICLE DRIVER INJURIES 11

OTHER VEHICLE: 1994 OLDSMOBILE CUTLASS SUPREME 11

CRASH DIAGRAM 13

CEREBRAL EDEMA AND BRAIN SWELLING 14

SELECTED PHOTOGRAPHS 15

 Figure 1: On-scene view of case vehicle and Oldsmobile at final rest positions 3

 Figure 2: Vertical view of case vehicle’s front right seating area 4

 Figure 3: Case vehicle’s frontal damage viewed from left of center 5

 Figure 4: Case vehicle’s frontal damage viewed from right of center 5

 Figure 5: Vertical view of case vehicle’s driver seating area 6

 Figure 6: Close-up of case vehicle’s misaligned front right air bag module’s
 cover flap 6

 Figure 7: Vertical view of case vehicle’s deployed front right air bag 7

 Figure 8: Case vehicle’s front seating area from right front door 8

 Figure 9: Close-up of “D”-ring from case vehicle’s front right safety belt 8

 Figure 10: Close-up of blood smear on case vehicle’s front right safety belt 8

 Figure 11: On-scene view of Oldsmobile’s front seating area showing non-
 deployed driver’s air bag 11

 Figure 12: On-scene view of Oldsmobile's right side damage 12

TABLE OF CONTENTS (CONTINUED)

IN97-018

	<u>Page No.</u>
SELECTED PHOTOGRAPHS (Continued)	
Figure 13: Case vehicle's front right seating area showing blood smears	15
Figure 14: On-scene view of case vehicle's front seating area from driver's door	15

This on-site investigation was brought to NHTSA's attention by an air bag advocacy group. This crash involved a 1994 Plymouth Voyager (case vehicle) and a 1994 Oldsmobile Cutlass Supreme (other vehicle). The crash occurred in May, 1996, at 8:59 a.m., in Illinois and was investigated by the applicable city police department. This crash is of special interest because the case vehicle's front right passenger [4-year-old, White (non-Hispanic) female] sustained critical brain and cervical injuries from her deploying front right air bag, resulting in her death. This contractor inspected the scene and vehicles on July 3, 1997. This contractor interviewed the case vehicle's driver on November 3, 1998. This report is based on the Police Crash Report, interviews with the investigating officer and the case vehicle's driver, scene and vehicle inspections, occupant kinematic principles, occupant medical records, and this contractor's evaluation of the evidence.

SUMMARY

The case vehicle was traveling northwest in the outside lane on a four-lane, divided state trafficway and intended to continue its northwestward path of travel (i.e., both the southeast and northwest roadways had two through lanes; the median was a paved-painted type with varying width). The Oldsmobile had been traveling southeast in the inside lane of the southeast roadway and was attempting a left turn across the northwest roadway into a parking lot driveway. The case vehicle's driver steered slightly to the right and braked attempting to avoid the crash. The crash occurred in the outside lane of the northwest roadway in the junction of the driveway.

The front of the case vehicle impacted the right side of the Oldsmobile, causing the case vehicle's driver and front right passenger supplemental restraints (air bags) to deploy. The case vehicle rotated approximately 45 degrees clockwise prior to coming to rest heading north, straddling the outside lane and the parking lot driveway. The Oldsmobile rotated approximately 90 degrees clockwise before coming to rest heading southeast, perpendicularly across the driveway.

The front right passenger [114 centimeters and 71 kilograms (45 inches, 44 pounds)] was wearing only her available, active, two-point lap belt, with her shoulder belt behind her. This improper usage enabled the passenger to lean farther forward and closer to the front right dash/air bag module just prior to impact. An inspection of the front right passenger's air bag, which was located in the top of the instrument panel, revealed traces of what appeared to be skin on the top and front portions. There was no evidence of contact on the front right passenger air bag module's cover flap; although, the cover flap was misaligned indicating that some sort of blockage occurred during the deployment sequence. The inspection of the front right passenger's seat belt webbing, "D"-ring, and latch plate showed evidence of loading. The upper anchorage was adjusted to the full down position. The webbing showed some evidence of fraying along the edges. The "D"-ring and latch plate, that the webbing travels through, each had evidence of heat abrasion to the rounded corners. The lap belt portion of the front right passenger's continuous loop seat belt also showed that approximately 40 centimeters (15.7 inches) of webbing was smeared with blood (both sides) and slightly rippled from stretching.

The case vehicle's driver steered slightly to the right and braked (i.e., the case vehicle was equipped with anti-lock brakes) attempting to avoid the crash. As a result of these attempted avoidance maneuvers and the improper use of her available safety belts, the front right passenger's upper torso moved essentially forward just prior to impact. The case vehicle's impact with the Oldsmobile enabled the case vehicle's front right passenger to continue forward and slightly leftward toward the case vehicle's **340** degree Direction of Principal Force as the case vehicle decelerated. This would have put the occupant's forward movement very close to the deploying air bag, which would explain the contact evidence to the top portion of the air bag. As the air bag deployed, the front right occupant was lifted upwards before being propelled backwards into her seat by the deploying air bag. After striking her seat back, the front right passenger rebounded back forward and to her left, toward the center instrument panel, because the case vehicle had rotated approximately 45 degrees clockwise as a result of its impact. At final rest, the front right occupant was laying sideways on the seat with her head hanging over the center edge of the seat, facing the case vehicle's driver.

The front right occupant was transported by ambulance to the hospital. She sustained critical injuries and was pronounced dead 21 hours post-crash. According to her medical records, the case vehicle's front right passenger sustained: critical brain injuries including severe edema and a diffuse axonal injury, and dislocations of the cervical vertebrae at C₁-C₂ (atlantoaxial) and C₂-C₃. This occupant's primary brain and cervical injuries were caused by her contact with the case vehicle's front right passenger air bag.

The 1994 Plymouth Voyager was a front wheel drive, three-door minivan (VIN: 2P4GH253XRR-----). The case vehicle was equipped with anti-lock brakes. The 1994 Oldsmobile Cutlass Supreme is a front wheel drive, two-door coupe (VIN: 1G3WH15M9RD-----). The case vehicle and the Oldsmobile were both towed from the scene due to damage. Based on the vehicle inspection, the CDC for the case vehicle was determined to be: **11-FDEW-1 (340 degrees)** [i.e., maximum crush was 10 centimeters (3.9 inches) at C₁ (**Figures 4 and 5**)]. The Oldsmobile had already been repaired, but based on the available photographs the Oldsmobile's CDC is estimated as: **02-RPMW-2 (60 degrees)**. The WinSMASH reconstruction program, missing vehicle algorithm (with CDC for the missing vehicle), was used on the case vehicle's highest severity impact. The Total, Longitudinal, and Lateral Delta V's are, respectively: 18.1 km.p.h. (11.2 m.p.h.), -17.1 km.p.h. (-10.6 m.p.h.), and +6.2 km.p.h. (+3.9 m.p.h.).

Immediately prior to the crash, the case vehicle's front right passenger was seated in an upright posture with her back against the seat back; however, the exact position of her legs and hands is unknown. The case vehicle's driver indicated that the front right seat was located between its middle and forward-most positions; however, during vehicle inspection the front right seat track was found to be located between its middle and rearmost positions. Furthermore, during the vehicle inspection the measured distance from the dash to the center of the front right occupant's seat back was 81 centimeters (32 inches). In this contractor's opinion, the front right seat track had been moved rearward post-crash.

The case vehicle's driver [37-year-old, White (non-Hispanic) female; 61 kilograms (135 pounds)] was seated in an upright posture with her back against the seat back, her left foot on the floor, her right foot on the brake, and both hands (at 10 and 2 o'clock positions) on the steering wheel. According to the case vehicle's driver, her seat track was located between its middle and forward-most positions, the seat back was upright, and the tilt steering wheel was located in its middle position. The vehicle inspection showed that her seat track was located in its rearmost position, the seat back was slightly reclined, and the tilt steering wheel was located in its middle position. Based on the driver's height (163 centimeters, 64 inches), the seat track was most likely moved prior to this contractor's inspection. An inspection of the driver's air bag, which was located in the steering wheel hub showed no visible evidence of contact. The case vehicle's driver was restrained by her available, active, three-point, lap and shoulder belt. The case vehicle's driver was transported by ambulance to the hospital, only to be with her daughter. She indicated that she did not sustain any injuries as a result of this crash.

CRASH CIRCUMSTANCES

The case vehicle was traveling northwest in the outside lane on a four-lane, divided state trafficway and intended to continue its northwestward path of travel [i.e., both the southeast and northwest roadways had two through lanes; the median was a paved-painted type with varying width—2 meters (6.6 feet) wide at its widest point]. The Oldsmobile had been traveling southeast in the inside lane of the southeast roadway and was attempting a left turn across the northwest roadway into a parking lot driveway. The northwestbound lanes were divided by dashed white lines with a solid white fog line along the roadway edges. Both bituminous roadways were dry and primarily straight with a vertical alignment of: +2% to the northwest, at the point of impact. Each vehicle's roadway width was 3.1 meters (10.2 feet); the roadways were curbed and had no shoulders. The area is a mixture of commercial and residential properties.

The case vehicle's driver steered slightly right and braked attempting to avoid the crash. The crash occurred in the outside lane of the northwest roadway in the junction of the driveway.

The front of the case vehicle impacted the right side of the Oldsmobile, causing the case vehicle's driver and front right passenger supplemental restraints (air bags) to deploy. The case vehicle rotated approximately 45 degrees clockwise prior to coming to rest heading north, straddling the outside lane and the parking lot driveway (**Figure 1**). The Oldsmobile rotated approximately 90 degrees clockwise before coming to rest heading southeast, perpendicularly across the driveway.



Figure 1: On-scene view of case vehicle (diagonally straddling outside lane) and Oldsmobile (toward left) at final rest positions; Note: both vehicles rotated clockwise post-impact (case photo #05)

The 1994 Plymouth Voyager was a front wheel drive , seven-passenger, three-door minivan (VIN: 2P4GH253XRR-----) equipped with a 3.0 liter, MPI, V-6 engine, a transverse mounted, four-speed automatic transmission, and power-assisted, rack-and-pinion steering. Braking was achieved by a hydraulic, power-assisted, front disc and rear drum anti-lock system. The case vehicle's wheel base was 250 centimeters (98.4 inches), and the odometer reading at inspection was 49,983 km (31,058 miles).

The interior of the Voyager was equipped with adjustable front bucket seats with integral head restraints, three-point lap and shoulder belts in the six outboard seated positions, and a lap belt in the rear center seat position. The second and rear seats were two and three seat bench seats respectively and neither were equipped with head restraints. The front belt systems were equipped with manually operated height adjusters for the "D"-rings, and buckle webbing assembly energy management loops. Automatic restraint was provided by a Supplemental Restraint System (SRS) that consisted of frontal air bags for the driver and front right passenger positions. The vehicle was also equipped with driver and front right rigid plastic knee bolsters.

Examination of the Voyager's interior showed what appeared to be a contact (scuff) to the driver's knee bolster by the driver's right knee. The windshield on the passenger side was starred towards the top of the glass by the deploying, top mounted air bag. In addition, residue from the air bag generant was found on the windshield. Further examination of the interior revealed a brush abrasion to the right front passenger's door handle from the deploying front right air bag. Another brush abrasion was found to the right side of the center instrument panel (Figure 2). The rear view mirror was knocked off by the deploying front right top mounted air bag.

CASE VEHICLE DAMAGE

The front bumper fascia of the case vehicle impacted the right side of the Oldsmobile, just behind the Oldsmobile's "A"-pillar. The direct contact damage extended across the entire front end, from bumper corner to bumper corner, a distance of 150 centimeters (59.1 inches). The initial bumper fascia contact with the Oldsmobile resulted in residual crush to the bumper reinforcement bar. The front bumper fascia, bumper reinforcement bar, and right fender were



Figure 2: Vertical view of case vehicle's front right seating area showing contact evidence to top of front right passenger air bag, right side of center instrument panel, and cover flap (yellow dots); Note: windshield contacted by deploying air bag (case photo #38)

shifted slightly to the right due to the **340** degree Direction of Principal Force (**Figure 3** and **Figure 4**). The residual crush to the front bumper and bumper reinforcement bar was 10 centimeters (4 inches) to the corners (C_1 and C_6) and 6 centimeters (2.4 inches) across the center. The wheelbase was not altered. The trim along the driver's door was peeled off. This most likely occurred post-crash when the driver open her door to exit the vehicle and struck the left fender, which had sustained induced damage.



Figure 3: Case vehicle's frontal damage with contour gauge present viewed from left of center; Note: front end shifted slightly to right (case photo #16)



Figure 4: Case vehicle's frontal damage with contour gauge present viewed from right of center; Note: front end shifted to right (case photo #27)

Based on the vehicle inspection, the CDC for the case vehicle was determined to be: **11-FDEW-1 (340 degrees)** [i.e., maximum crush was 10 centimeters (3.9 inches)]. The WinSMASH reconstruction program, missing vehicle algorithm (with CDC for the missing vehicle), was used on the case vehicle's highest severity impact. The Total, Longitudinal, and Lateral Delta V's are, respectively: 18.1 km.p.h. (11.2 m.p.h.), -17.1 km.p.h. (-10.6 m.p.h.), and +6.2 km.p.h. (+3.9 m.p.h.). The case vehicle was towed from the scene due to damage.

AUTOMATIC RESTRAINT SYSTEM

The case vehicle was equipped with a Supplemental Restraint System (SRS) that contained frontal air bags at the driver and front right passenger positions. Both air bags deployed as a result of the frontal impact with the Oldsmobile. The driver's air bag deployed from the steering wheel hub where it was mounted. The module cover consisted of symmetrical cover flaps with overall dimensions of 17.5 centimeters (6.9 inches) at the horizontal seam and 6.5 centimeters (2.6 inches) vertically. The air bag was untethered and was 63 centimeters (24.8 inches) in diameter. The driver's air bag was vented by two, 2.5 centimeter (1 inch) diameter vent ports that were located in the 11 and 1 o'clock sectors of the air bag. There was no visible evidence of direct contact to the driver's air bag (**Figure 5** below) from either occupant's involvement.

The front right passenger air bag module was mounted in the top of the right instrument panel. The module had a single forward hinged cover flap. The cover flap was made of a vinyl

skin over a sheet metal frame/liner which acted as the hinge point for the deploying flap. The flap appeared to be shifted with the upper right corner being pushed toward the windshield and the lower left being pulled inwards. The passenger's forward movement momentarily impeded the deploying air bag, altering its normal deployment path, and causing the cover flap to shift in order for the air bag to fully deploy (**Figure 6**). The air bag was deflected in an upward direction, by the front right passenger's head, against the windshield where it contacted and fractured the windshield in a star like pattern (**Figure 2** above). The single flap's dimensions were 32 centimeters (12.6 inches) horizontally and 15 centimeters (5.9 inches) deep, toward the windshield. The design of the case vehicle's right instrument panel resulted in a 3 centimeter (1.2 inch) setback of the cover flap's leading edge relative to the forward edge of the right instrument panel.

The cover flap opened at the designated tear points which were located along the leading and outer edges of the flap. The hinged flap did not contact the windshield in this crash. There were two areas of suspected contact present on the front right air bag module's cover flap. One was toward the left leading edge and measured 5 centimeters (2.0 inches) wide and 3 centimeters (1.2 inches) deep and had the appearance of a grease smudge. The other area of suspected contact was to the front right corner and extended back along the right side. This second area was whitish, with a dimension of 7 centimeters (2.8 inches) square, and had the appearance of three finger shaped marks. Based on this and the previously mentioned altered air bag deployment path, this contractor believes that the cover flap was directly contacted during deployment. However, the medical was silent regarding any possible right hand injuries.

Examination of the front right passenger air bag revealed a large amount of skin to the top and the front portions of the air bag and a fair amount of black scuffing (**Figure 2** above and **Figure 7** below). The black scuffing most likely came from the underside surface of the cover



Figure 5: Vertical view of case vehicle's driver seating area; Note: no visible evidence of contact to driver's air bag (case photo #30)



Figure 6: Close-up view of case vehicle's misaligned front right air bag module's cover flap, indicating the air bag's deployment path was momentarily altered/blocked (case photo #47)

flap during the deployment sequence when the bags deployment path was momentarily impeded. The skin and black scuffing evidence at the top of the air bag was 27 centimeters (10.6 inches) wide and started 5 centimeters (2.0 inches) to the right of the left edge of the air bag and just 12 centimeters (4.7 inches) from the leading edge of the cover flap. The skin evidence extended forward (toward the passenger) 25 centimeters (9.8 inches) to the top horizontal edge of the air bag. The black scuffing continued down the front of the air bag for an additional 14 centimeters (5.5 inches) and started again 24 centimeters (9.4 inches) farther down for 7 centimeters (2.8 inches), both being 21 centimeters (8.3 inches) in from right side edge. The skin evidence started again approximately 21 centimeters (8.3 inches) down from the top horizontal edge for a distance of 26 centimeters (10.2 inches).

The front right passenger air bag was tethered by two wide-band, internal straps that were 32 centimeters (12.6 inches) in width. The tethers were sewn internally to the face of the passenger air bag. The upper tether was sewn at a point that was approximately 21 centimeters (8.3 inches) below the top horizontal edge of the bag, and the lower tether was sewn approximately 29 centimeters (11.4 inches) below upper tether and 16 centimeters (6.3) above the bottom horizontal edge. The air bag's front face was 47 centimeters (18.5 inches) wide and 66 centimeters (26 inches) tall. The passenger air bag had no vent ports.



Figure 7: Vertical view of case vehicle's front right passenger seating area and deployed front right air bag; Note: skin evidence on front portion of air bag, highlighted by yellow tape (case photo #42)

CASE VEHICLE FRONT RIGHT PASSENGER KINEMATICS

Based on the driver's interview, the front right passenger [4-year-old, White, non-Hispanic female, 114 centimeters and 71 kilograms (45 inches, 44 pounds)] was sitting upright with her back against the seat back just prior to the crash. The positions of her feet, legs, and hands are unknown. She was wearing only her available, active, two-point lap belt, with her shoulder belt behind her. It is possible that because of the passenger's short stature the shoulder portion did not engage the passenger's shoulder. The case vehicle's driver indicated that the front right seat was located between its middle and forward-most positions; however, the during vehicle inspection the front right seat track was found to be located between its middle and rearmost positions (**Figure 8** below). Furthermore, during the vehicle inspection the measured distance from the dash to the center of the front right occupant's seat back was 81 centimeters (32 inches). In this contractor's opinion, the front right seat track had been moved rearward post-crash.

The case vehicle's driver steered slightly to the right and braked (the case vehicle was equipped with anti-lock brakes) attempting to avoid the crash. As a result of these attempted avoidance maneuvers, the passenger's seat belt system locked prior to impact, but because of the improper use of her available safety belts, the front right passenger's upper torso moved essentially forward toward the right instrument panel and the air bag module just prior to impact.



Figure 8: Case vehicle's front seating area viewed from right front door; Note: seat back and seat track positions at inspection, skin evidence to top of front right passenger's air bag, and air bag module's cover flap (case photo #35)

The case vehicle's impact with the Oldsmobile enabled the case vehicle's front right passenger to continue forward and slightly leftward toward the case vehicle's 340 degree Direction of Principal Force as the case vehicle decelerated. This would have put the occupant's forward movement very close to the deploying air bag module, which could explain the oil smear to the left side of the top mounted cover flap and the possible finger shaped marks on the top right portion.



Figure 9: Close-up of "D"-ring from case vehicle's front right passenger seat belt showing heat abrasion indicating some type of usage during crash (case photo #60A)

The inspection of the front right passenger's seat belt webbing, "D"-ring, and latch plate showed evidence of loading. The upper anchorage was adjusted to the full down position. The webbing showed some evidence of fraying along the edges. The "D"-ring and latch plate that the webbing travels through, each had evidence of heat abrasion to the rounded corners. In essence, the slack from having the shoulder belt behind her allowed the front right passenger to move farther



Figure 10: Close-up of blood smear on lap portion of case vehicle's front right seat belt webbing (case photo #60)

forward, and the slack running through the “D”-ring caused the heat abrasion (**Figure 9** above). The lap belt portion of the front right passenger's continuous loop seat belt also showed that approximately 40 centimeters (15.7 inches) of webbing was smeared with blood (both sides) and slightly rippled from stretching (**Figure 10** below and see **SELECTED PHOTOGRAPHS**, specifically **Figure 13** below).

The front right passenger's face and neck contacted the top portion of the air bag. The passenger's chest simultaneously contacted the front portion of the air bag as it expanded. As the air bag deployed, the front right passenger was lifted upwards, partially out of her lap belt (i.e., as reported in her medical records), resulting in her critical injuries. Subsequently, she was propelled backwards into her seat by the deploying air bag. After striking her seat back, the front right passenger rebounded back forward and to her left, toward the center instrument panel, because the case vehicle had rotated approximately 45 degrees clockwise as a result of its impact. According to the driver, at final rest, the front right occupant was laying sideways on the seat with her head hanging over the center edge of the seat, facing the case vehicle's driver. Her legs were curled up in a fetal position with the lap belt still attached. Following the crash the mother removed the front right passenger through the driver door and laid her down on the grass.

CASE VEHICLE FRONT RIGHT PASSENGER INJURIES

The front right occupant was transported by ambulance to the hospital. She sustained critical injuries and was pronounced dead 21 hours post-crash. According to her medical records, the case vehicle's front right passenger sustained: critical brain injuries including severe edema and a diffuse axonal injury, and dislocations of the cervical vertebrae at C₁-C₂ (atlantoaxial) and C₂-C₃. This occupant's primary brain and cervical injuries were caused by her contact with the case vehicle's front right passenger air bag.

Injury Number	Injury Description (including Aspect)	NASS Injury Code & AIS 90	Injury Source (Mechanism)	Source Confidence	Source of Injury Data
1	Nonanatomic brain injury, unconscious, no response to deep pain, GCS=3	160824.5 critical	Air bag, front right passenger's	Certain	Hospitalization records
2	Edema ¹ , cerebral, severe ² ; [Aspect = Unknown]	140666.5 critical	Air bag, front right passenger's	Certain	Hospitalization records
3	Injury, diffuse axonal (white matter shearing) [Aspect = Unknown]	140628.5 critical	Air bag, front right passenger's	Certain	Emergency room records

¹ Edema was cited by the initial treatment facility; the "transported to" facility cited brain swelling. For a discussion of the difference, see **CEREBRAL EDEMA AND BRAIN SWELLING** below.

² Severe is the best fit. The initial medical facility indicated that the lateral ventricles were somewhat compressed while the third ventricle was either markedly narrowed or not visualized and the fourth ventricle was essentially not visualized. The "transferred to" facility cited massive ventricular compression and a very small basilar cistern. The initial facility indicated that the basilar and suprasellar cisterns were obliterated.

Injury Number	Injury Description (including Aspect)	NASS Injury Code & AIS 90	Injury Source (Mechanism)	Source Confidence	Source of Injury Data
4	Hemorrhage, subarachnoid [Aspect = Unknown]	140684.3 severe	Air bag, front right passenger's	Certain	Emergency room records
5	Fracture odontoid (dens) with odontoid dislocation	650228.3 severe	Air bag, front right passenger's	Probable	Hospitalization records
6	Atlantoaxial dislocation with 8 millimeter {50%} anterior displacement of C ₁ on C ₂ and probable cervical cord injury	650206.3 severe	Air bag, front right passenger's	Certain	Hospitalization records
7	Dislocation {subluxation ³ } of C ₂ anteriorly relative to C ₃	650204.2 moderate	Air bag, front right passenger's	Certain	Hospitalization records
8	Abrasions with swelling throughout her whole face	290202.1 minor	Air bag, front right passenger's	Certain	Emergency room records
9	Contusion {hematoma} to left forehead	290402.1 minor	Center instrument panel	Probable	Emergency room records
10	Contusion {hematoma} to bridge of nose	290402.1 minor	Air bag, front right passenger's	Probable	Emergency room records
11	Abrasions on right lower quadrant, not further specified	590202.1 minor	Front right seat belt, lap portion	Probable	Emergency room records
12	Contusion {bruise} to right side of pelvis	890402.1 minor	Front right seat belt, lap portion	Probable	EMS treatment record
13	Contusion {bruising} to right thigh, not further specified	890402.1 minor	Front right seat belt, lap portion	Probable	Emergency room records

CASE VEHICLE DRIVER KINEMATICS

The case vehicle's driver [37-year-old, White (non-Hispanic) female; 61 kilograms (135 pounds)] was seated in an upright posture with her back against the seat back, her left foot on the floor, her right foot on the brake, and both hands (at 10 and 2 o'clock positions) on the steering wheel. According to the case vehicle's driver, her seat track was located between its middle and forward-most positions (see **SELECTED PHOTOGRAPHS**, specifically **Figure 14** below), the seat back was upright, and the tilt steering wheel was located in its middle position. The vehicle inspection showed that her seat track was located in its rearmost position, the seat back was slightly reclined, and the tilt steering wheel was located in its middle position. The case vehicle's driver was restrained by her available, active, three-point, lap-and-shoulder, safety belt system. The inspection of the driver's seat belt webbing, "D"-ring, and latch plate showed evidence of heat abrasion to the rounded corners of the "D"-ring but no separation of the buckle webbing assembly energy management loop. There was a small blood smear found on the backside of the driver's seat belt webbing on the lap belt portion near the buckle area. This most likely came from the

³ This lesion was also described as a complete disassociation.

driver's right hand as she went to unbuckle her belt after tending to the injured front right passenger. The upper anchorage for the driver's shoulder belt was adjusted between the middle and full down position. The interior inspection also revealed a smear of blood on the driver's seat back which occurred as the driver removed the front right passenger from the case vehicle through the driver door following the crash.

As a result of the driver's braking maneuver, her upper torso leaned forward just prior to impact. The case vehicle's impact with the Oldsmobile deployed both the driver the front right passenger air bags. The driver's seat belt system subsequently locked up restricting the driver's forward movement toward the steering wheel and air bag module. The case vehicle's impact with the Oldsmobile enabled the case vehicle's driver to continue forward and slightly leftward toward the case vehicle's **340** degree Direction of Principal Force as the case vehicle decelerated. An inspection of the driver's air bag, which was located in the steering wheel hub, showed neither visible evidence of contact (**Figure 5** above) nor was there compression of the energy absorbing steering wheel.

CASE VEHICLE DRIVER INJURIES

The case vehicle's driver was transported by ambulance to the hospital, only to be with her daughter, and was not treated. She indicated that she did not sustain any injuries as a result of this crash.

OTHER VEHICLE

The 1994 Oldsmobile Cutlass Supreme is a front wheel drive, five-passenger, two-door coupe (VIN: 1G3WH15M9RD-----) equipped with a 3.1L, MFI, V-6 engine and a four-speed automatic transmission. Four wheel anti-lock brakes are standard for this model. The case vehicle's wheel base was 273 centimeters (107.5 inches), and the odometer reading is unknown because no vehicle inspection occurred.

Based on an on-scene photograph and the VIN, the Oldsmobile was equipped with front bucket seats with folding backs and adjustable head restraints. The front outboard seats were equipped with automatic, three-point lap-and-shoulder restraints placed in the door frames. The Oldsmobile was also equipped with a driver air bag which did not deploy as a result of the right side impact (**Figure 11**).

The direct damage to the Oldsmobile extended from the right "A"-pillar rearward to approximately just forward of the right rear wheel (**Figure 12** below). The right front door glazing appeared to be disintegrated from the side impact. It is unknown if there was any intrusion to the front right seating position.




Figure 11: On-scene view of Oldsmobile's front seating area showing non-deployed driver's air bag and automatic seat belts (case photo #72)

Other Vehicle (Continued)

IN97-018

Based on the available photographs, the CDC for the Oldsmobile was determined to be: **02-RPMW-2 (60 degrees)**. The WinSMASH reconstruction program, missing vehicle algorithm (with CDC only for the Oldsmobile), was used on the Oldsmobile's highest severity impact. The Total, Longitudinal, and Lateral Delta V's are, respectively: 19.2 km.p.h. (11.9 m.p.h.), -9.6 km.p.h. (-6.0 m.p.h.), and -16.6 km.p.h. (-10.3 m.p.h.). The Oldsmobile was towed from the scene due to damage.

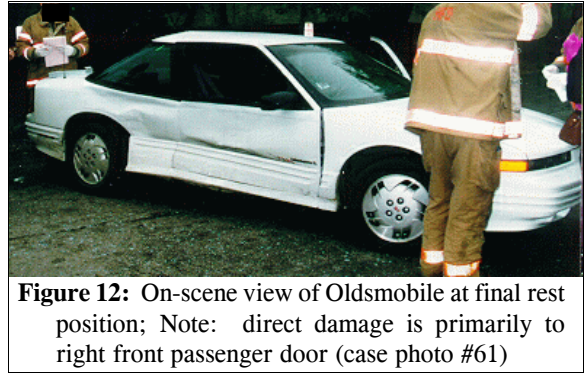
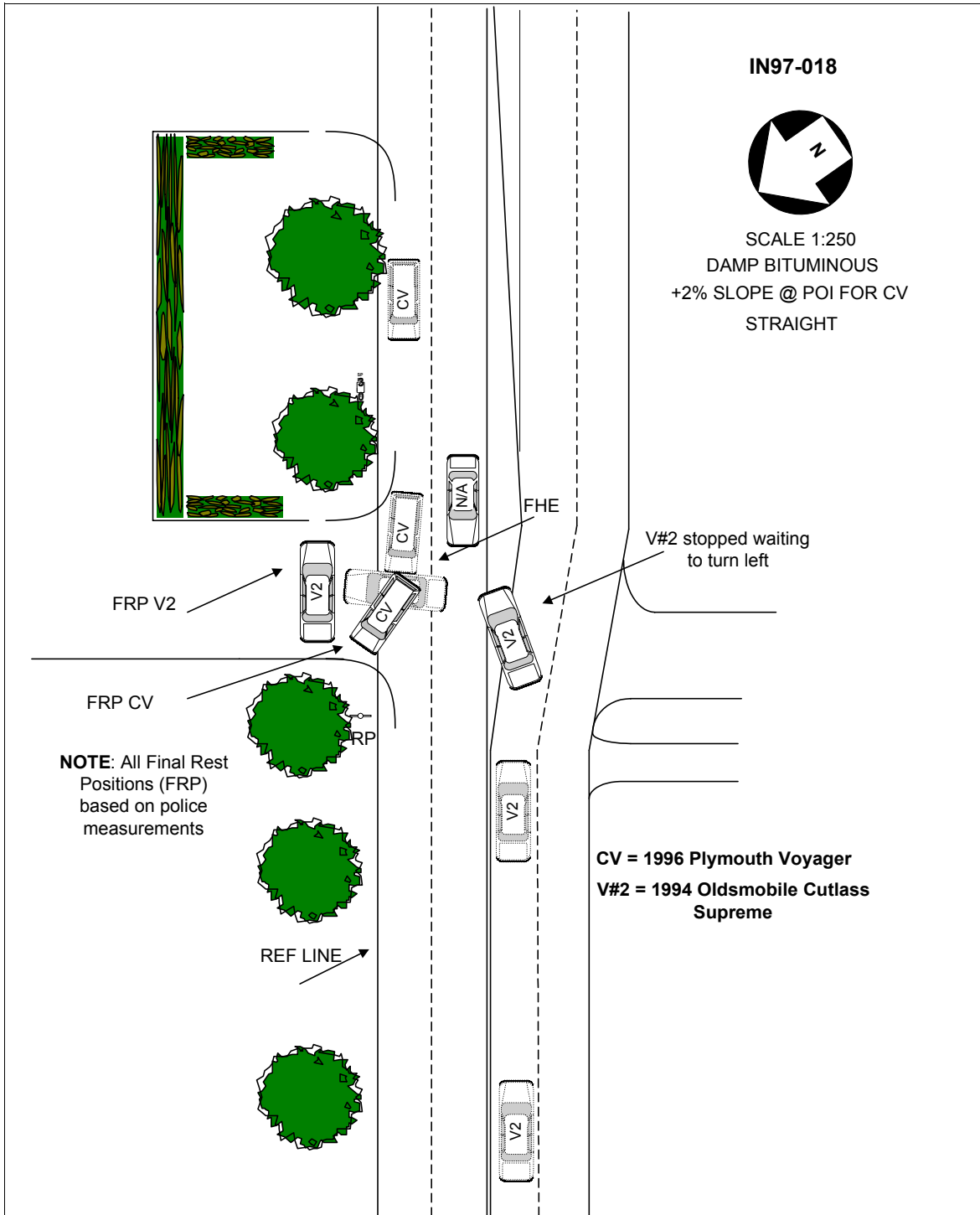


Figure 12: On-scene view of Oldsmobile at final rest position; Note: direct damage is primarily to right front passenger door (case photo #61)



The following material is taken from the book: FORENSIC PATHOLOGY, 2ND EDITION by Vincent J. DiMaio, M.D., and Dominick J. DiMaio, M.D., CRC Press, Boca Raton, Florida, 2001; Chapter Six: Trauma to the Skull and Brain: Craniocerebral Injuries, *Traumatic Brain Swelling and Edema*, pages 177-179.

Following significant head injury, whether clinically mild or severe, swelling of the brain may occur. Brain swelling may be focal, adjacent to an area of brain injury; or diffuse, involving one or both cerebral hemispheres. **BRAIN SWELLING** is due to an **increase in intravascular cerebral blood volume secondary to vasodilation (congestive brain swelling) or an absolute increase in the water content of the brain tissue**, or a combination of the two. An increase in tissue water content, or **CEREBRAL EDEMA**, is often incorrectly considered synonymously with brain swelling. If continued long enough, brain swelling caused by an increase in the intravascular cerebral blood volume progresses to cerebral edema, presumably due to increased vascular permeability. The magnitude of the brain swelling does not necessarily correspond to the severity of the injury. Massive cerebral (congestive) swelling can occur within 20 minutes following head trauma.

Swelling of one cerebral hemisphere is seen most commonly with an ipsilateral⁴ subdural hematoma. The secondary swelling may, in fact, cause a more serious mass effect than the original hematoma. The rapid onset of the swelling suggests that the etiology is congestive.

With severe brain injury, diffuse brain swelling of a severe degree may occur immediately without the individual regaining consciousness. Brain swelling, however, may not occur immediately after an injury, but rather develop minutes to hours later. Delayed brain swelling of a significant degree is rare. It is usually diffuse and more often associated with the less severe forms of brain injury. Typically, the patient receives a concussion {*non-anatomic brain injury*}, regains consciousness, only to become stuporous and lapse into coma minutes to hours later. Until recently, it was felt that children were more susceptible than adults to developing diffuse swelling, even after minor trauma. Recent studies have challenged this contention. Lang et al. found that, while diffuse swelling might occur more readily in children it is more benign. Thus, in their study 75% of children with diffuse swelling had a benign course, while two thirds of adults had a poor outcome. The researchers believed that a number of the previous studies had problems in that they were not able to adequately study changes in the brain in children because the studies were performed without CT scans.

⁴ The following term is defined in DORLAND'S ILLUSTRATED MEDICAL DICTIONARY as follows:
ipsilateral (ip"ŝ Qat'ar-al): situated on, pertaining to, or affecting the same side, as opposed to contralateral.



Figure 13: Case vehicle's front right seat belt showing area of blood smear (taped area) and blood spots (yellow dots) to seat cushion and seat back (case photo #34A)



Figure 14: On-scene view of case vehicle's front seating area showing deployed front air bags and driver's seat track location (case photo #33)